

Eyup Altinoz<sup>1</sup>, Emre Taskin<sup>2</sup>, Zulal Oner<sup>3</sup>, Hulya Elbe<sup>4</sup>, Belkis Atasever Arslan<sup>5</sup>

<sup>1</sup>Karabuk University, Faculty of Medicine, Department of Medical Biochemistry, Karabuk, Turkey,

<sup>2</sup>Karabuk University, Faculty of Medicine, Department of Medical Biology and Genetics, Karabuk, Turkey., <sup>3</sup>Inonu University, Faculty of Medicine, Department of Anatomy, Malatya, Turkey. <sup>4</sup>Mugla Sitki Kocman University, Faculty of Medicine, Department of Histology and Embryology, Mugla, Turkey. <sup>5</sup>Uskudar University, Faculty of Engineering and Natural Sciences, Department of Molecular Biology and Genetics, Istanbul, Turkey.

**Corresponding Author: E-mail:** [eyupaltinoz@karabuk.edu.tr](mailto:eyupaltinoz@karabuk.edu.tr), [emretaskin@k.arabuk.edu.tr](mailto:emretaskin@k.arabuk.edu.tr), [zulaloner@karabuk.edu.tr](mailto:zulaloner@karabuk.edu.tr), [h\\_elbe@hotmail.com](mailto:h_elbe@hotmail.com), [belkisatasever.arslan@uskudar.edu.tr](mailto:belkisatasever.arslan@uskudar.edu.tr)

## Abstract

**Background:** Diabetes mellitus (DM) causes serious complications such as coronary heart disease, atherosclerosis, nephropathy, retinopathy and neuropathy.

**Materials and Methods:** Rats were randomly divided into three groups, each containing 10 rats: control group, DM group; DM+crocin group. Normal saline was administered in the control and DM groups, and crocin was administered in DM+crocin group at a dose of 20 mg/kg bw/day for 21 days. Trunk blood and the heart tissue were collected for histopathological and biochemical examination.

**Results:** DM led to increment of MDA levels ( $p<0.05$ ) and the serum levels of total cholesterol, TG, LDL and VLDL ( $p<0.05$ ) and decrease of GSH levels ( $p<0.01$ ) compared to control group in serum and heart tissue. Diabetic rats were treated with crocin, MDA levels ( $p<0.05$ ) and the levels of total cholesterol, TG and VLDL decreased significantly, but GSH levels ( $p<0.05$ ) increased remarkably compared to DM rats. Statistically significant increase in histopathological damage score was found in the DM group ( $p<0.0001$ ). Histopathological changes markedly regressed in DM+crocin group.

**Conclusion:** Our results showed that crocin might prevent diabetes induced cardiovascular complications by reduction of oxidative stress and dyslipidemia.

**Key words:** Oxidative stress, MDA, GSH, crocin, Diabetes, dyslipidemia.

## Introduction

Diabetes mellitus (DM) is a chronic disorder of carbohydrate, fat and protein metabolism characterized by high level of glucose in the blood due to the absence of insulin secretion from  $\beta$  cells or insulin insensitivity (Vardi et al., 2003). DM causes serious complications such as coronary heart disease, atherosclerosis, nephropathy, retinopathy and neuropathy (Militante et al., 2000).

Coronary artery disease is one of the major complications of oxidative stress (Samarghandian et al., 2014). It has been shown that patients with diabetes have the greater risk of cardiovascular diseases (Wang and Reusch, 2012). Previous studies have demonstrated that both type 1 and type 2 diabetes lead to increase in oxidative stress and depletion of antioxidant defense systems due to elevated formation of free radicals (Rahimi et al., 2005).

Oxidative stress results from an imbalance of oxidants/antioxidants in favour of oxidants. The generation of free oxygen radicals and Reactive Oxygen Species (ROS) causes oxidative stress. ROS have toxic effects on all components of the cell, including protein, lipid, DNA and particularly cell membrane in which they react with membrane phospholipids and cause to production of lipid peroxidation (Bast et al., 1991). ROS play an important role in the pathogenesis of many complications such as hypoxia, hypercholesterolemia, hypertension, ischemia reperfusion injury, atherosclerosis and heart failure (Wilcox and Gutterman, 2005).

Malondialdehyde (MDA), a biomarker for oxidative stress, is generated endogenously by lipid peroxidation (Esterbauer, 1993). It has been shown that glutathione (GSH) deficiency is associated with pathophysiology of many diseases including cancer, neurodegenerative and cardiovascular diseases (Cotgreave and Gerdes, 1998).

Saffron is the dried stigma of *Crocus Sativus* L. and is used in medicine for treatment of cancer and mental disorders (Fratelli et al., 2002). Saffron contains three main pharmacologically active metabolites. They are crocins, which are unusual water-soluble carotenoids (mono and diglycosyl esters of a polyene dicarboxylic acid, named crocetin); picrocrocins and safranal (Srivastava et al., 2010). It has been shown that saffron and its active constituents have a wide variety of pharmacological effects such as antigenotoxic, neuroprotective, analgesic, antihypertensive, antihyperlipidemic and anti-inflammatory effects (Farahmand et al., 2013).

In addition, saffron, crocin, crocetin and safranal have high antioxidant activity by scavenging free radicals (Chen et al., 2008). Antidiabetic drugs do not effectively provide protection against complications of diabetes such as oxidative stress (Gilbert and Pratley, 2009).

Thus, studies that focused on plant originating antioxidants are getting more popular. Crocetin is capable of increasing insulin sensitivity and preventing complications associated with insulin resistance such as disrupted glucose tolerance, dyslipidemia, hyperinsulinemia and hypertension due to high fructose diet and dexamethasone injection in rats (Xi et al., 2007).

In addition, crocetin inhibited adhesion of leukocytes to the bovine aortic endothelial cells (BEC) (Xiang et al., 2006b). Dyslipidemia is a condition which levels of blood lipid fractions are dysregulated (Bhalodia et al., 2010). Blood lipids usually increase in DM and play an important role in coronary artery disease. Diabetes and hypercholesterolemia are the main reasons of endothelial dysfunction (Kolluru et al., 2012).

The aim of this study was to determine the effects of crocin on cardiovascular complication, dyslipidemia and oxidative stress by measuring MDA and GSH levels in serum and heart tissue as well as serum lipid levels in streptozotocin induced diabetic rats.

## Material and Methods

### Experimental Animals

In this study, 30 female Wistar rats weighing 170-200 g were obtained from the Inonu University Faculty of Medicine – Experimental Research Department. Animals were housed in colony rooms with 12/12 h light/dark cycle at 21°C, 55-60 % humidity and fed with rat, cow and given water *ad libitum*. The experimental protocol was evaluated and approved by the Ethics Review Committee of Inonu University, Faculty of Medicine, Malatya, Turkey.

### Experimental Design

At the onset of the study, a blood sample was taken from tail vein of each rat for the measurement of blood glucose levels. Rats were randomly divided into three groups each containing 10 rats as follows; group 1, control (nondiabetic rats); group 2, DM (STZ-induced untreated diabetic rats); group 3, DM+crocin (STZ-induced diabetic rats treated with crocin.).

Streptozotocin (STZ; Sigma Chemical Co., St. Louis, MO, USA) which was dissolved in 0.01 M sodium citrate buffer (pH 4.5) was injected intraperitoneally (i.p.) at a single dose of 50 mg/kg body weight (bw) in DM and DM+crocin groups. 1 mL citrate buffer alone was injected i.p. in control group. After 3 days of STZ administration, blood glucose levels from tail vein were measured using reagent strip (Accu-Check Active Glucose test strips, ROCHE, Germany) with glucometer (Accu-Check Active, ROCHE, Germany).

Blood glucose levels of control group were in normal levels. STZ and STZ+crocin groups were accepted as diabetic because blood glucose levels were above 270 mg/dL. Normal saline was administered in the control and DM groups, and crocin (Sigma Chemical Co., St. Louis, MO, USA) dissolved in normal saline was administered at a dose of 20 mg/kg bw/day (Zheng et al., 2007). All administrations were performed at the same hour and with a volume of 5 mL/kg bw/day by gavage and continued for 21 days. At the end of the study, all rats were decapitated under the xylazine (Bayer Birlesik Alman I'lac, Fabrikalari T.A.S., Istanbul, Turkey) and ketamine (Parke Davis, Istanbul, Turkey) anesthesia at the dose of 10 mg/kg and 50 mg/kg respectively. Trunk blood was collected for measuring GSH, MDA and lipid levels of serum.

The heart tissue was removed rapidly and divided into two equal pieces. One of the pieces was placed into 10% formaldehyde for routine histopathological examination. The other piece was stored at -80 °C for the measurement of MDA and GSH levels.

### Biochemical Analysis

#### Measurement of Serum Lipid Profile

Blood samples for the measurement of serum lipids were extracted to determine drawn into tubes and immediately placed on ice. All tubes were centrifuged within several minutes of collection. The levels of triglycerides (TG), total cholesterol, low-density lipoprotein (LDL), very-low density lipoprotein (VLDL) and high-density lipoprotein (HDL) in serum were performed by using commercially available Architect c 1600 automatic analyzer kits (Abbott, Abbott Park, Illinois, USA). Results were expressed as mg/dL.

#### Measurement of Serum MDA Levels

The formation of MDA was measured in the serum. The main principle of the analysis is based on the fact that MDA in the medium reacts when heated with thiobarbituric acid and creates a pink chromogen. The intensity of the pink color is in direct proportion to MDA concentration. MDA levels were assayed spectrophotometrically at 535 nm according to the method described by Ohkawa et al (Ohkawa et al., 1979). Results were expressed as  $\mu\text{mol/L}$ .

#### Measurement of Serum GSH Levels

GSH levels were measured by the method followed by Ellman (Ellman, 1959). GSH is reacted with 5,5-dithiobis-2- nitrobenzoic acid resulting in the formation of a product which has a maximal absorbance at 410 nm. Results were expressed as  $\mu\text{mol/L}$ .

#### Measurement of Heart MDA and GSH Levels

The heart tissue was homogenized in ice within 10 volumes (w/v) of 0.1 M Tris (hydroxymethyl) aminomethane–hydrochloric acid buffer (pH 7.5; includes protease inhibitor, phenylmethylsulfonyl fluoride, 1 mM) via homogenizer (IKA Ultra Turrax T25 basic, IKA Labortechnik, Staufen, Germany) at 16,000 r/min and at +4 °C for 3 min. The supernatants were used for the measurement of MDA and GSH levels. The results of heart tissue were expressed as nanomoles per gram wet tissue.

### Histological Determination

Heart tissues were fixed in 10% formalin and were embedded in paraffin. The 5  $\mu\text{m}$  sections were stained with hematoxylin-eosin (H-E) and examined for severity of cardiac damage such as hemorrhage, vacuolization, infiltration and loss of myofibril in 10 different fields for each section. For this analysis, cardiac damage was semiquantitatively graded as absent (0), mild (1), moderate (2), and severe (3), for each criterion. The maximum histopathological damage score was 12. All sections were examined using a Leica DFC280 light microscope and a Leica Q Win and Image Analysis system (Leica Micros Imaging Solutions Ltd., Cambridge, UK).

## Statistical Analysis

Data were analyzed using Statistical Package for Social Sciences for Windows version 13.0 (SPSS Inc., Chicago, Illinois, USA) statistical program. Histopathological and biochemical results were expressed as mean±SD. Normality for continued variables in groups was determined by the Shapiro–Wilk test. The variables did not show normal distribution ( $p < 0.05$ ). Kruskal–Wallis and Mann–Whitney U tests were used for comparison of variables among the studied groups. The value of  $p < 0.05$  was considered statistically significant.

## Results

Table 1 presents the levels of MDA and GSH in the serum and the heart tissue respectively. Briefly, DM led to increment of MDA levels ( $p < 0.05$ ) and decrease of GSH levels ( $p < 0.01$ ) compared to control group. When diabetic rats were treated with crocin, MDA levels ( $p < 0.05$ ) decreased significantly, but GSH levels ( $p < 0.05$ ) increased remarkably compared to DM rats. Furthermore, MDA and GSH levels ( $p < 0.05$ ) were close to control group values through the effect of crocin.

Table 1: Effect of crocin on serum and heart tissue levels of MDA and GSH.

Groups	Serum		Heart Tissue	
	MDA ( $\mu\text{mol/L}$ )	GSH ( $\mu\text{mol/L}$ )	MDA (nmol/g wet tissue)	GSH (nmol/g wet tissue)
Control	166±16	136±21	166±9	270±38
DM	312±45 <sup>a</sup>	106±68 <sup>c</sup>	264±13 <sup>d</sup>	164±19 <sup>d</sup>
DM + Crocin	235±27 <sup>b</sup>	126±30 <sup>b</sup>	183±7 <sup>e</sup>	264±21 <sup>e,c</sup>

Values are expressed as mean±SD. <sup>a</sup> $p < 0.05$  vs control rats; <sup>b</sup> $p < 0.05$  vs diabetic rats; <sup>c</sup> $p < 0.01$  vs control rats; <sup>d</sup> $p < 0.01$  vs control rats; <sup>e</sup> $p < 0.05$  vs control rats.

Table 2 presents serum lipid levels of all groups. Diabetes caused significant increase serum total cholesterol, TG, LDL and VLDL ( $p < 0.05$ ) levels when compared to control group. However, HDL did not decrease significantly in DM group. After diabetic rats were treated with crocin, total cholesterol, TG and VLDL levels decreased remarkably, but LDL did not decrease significantly. Also, HDL did not increase remarkably in DM+crocin group.

Table 2: Effect of crocin on serum lipid profiles.

Groups	Cholesterol (mg/dL)	Triglyceride (mg/dL)	LDL (mg/dL)	VLDL (mg/dL)	HDL (mg/dL)
Control	45±1.5	66±8	11±1.6	13±1.6	20±0.9
DM	59±2.1 <sup>a</sup>	102±12 <sup>a</sup>	18±6.1 <sup>a</sup>	23±3.7 <sup>a</sup>	18±0.8
DM + Crocin	46±6.2 <sup>b</sup>	60±10 <sup>b</sup>	16±2.2	12±2.1 <sup>b</sup>	21±1

Values are expressed as mean±SD. <sup>a</sup> $p < 0.05$  vs control rats; <sup>b</sup> $p < 0.05$  vs diabetic rats.

The heart tissue in the control group was normal in histological appearance (Figure 1A). However, in the DM group, extensive hemorrhagic areas (Figures 1B, 1D), cytoplasmic and perinuclear myocardial vacuolization (Figures 1C, 1D), common inflammatory of cells (Figure 1E) and additionally in some areas, loss of myofibril (Figure 1F) were detected. Statistically significant increase in histopathological damage score was found in the DM group when compared to the control group ( $p < 0.0001$ ). On the other hand, these histopathological changes markedly regressed in DM+crocin group (Figures 1G, H). When DM group and DM+crocin group were compared, a statistically significant difference was detected ( $p < 0.001$ ). The histopathological damage score for each group was given in Table 3.

Table 3. The histopathological damage score of all groups.

	Group 1 Control	Group 2 DM	Group 3 DM + Crocin
Histopathologic damage score	0.00±0.00	8.50±0.32 <sup>a</sup>	3.00±0.26 <sup>a,b</sup>

Data are expressed arithmetic mean±SE of animals.

<sup>a</sup> $P < 0.0001$  vs group 1. <sup>b</sup> $P < 0.001$  vs group 2.

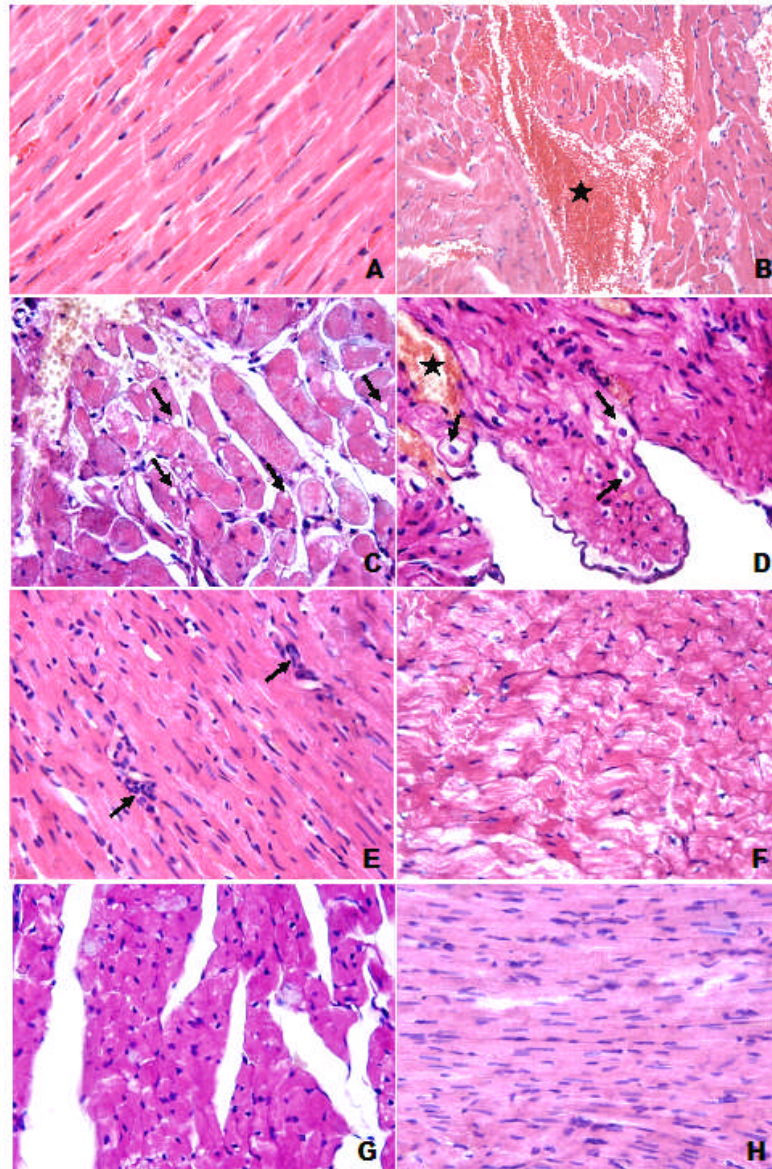
## Discussion

The main results of the present study demonstrate that crocin treatment significantly ameliorates oxidative stress and elevates lipid profile in diabetic rats.

This is the first histological and biochemical study evaluating the effects of crocin on STZ-induced cardiac complication. In the present study, we have found that crocin has protective effect against oxidative stress in serum and heart tissue of STZ-induced diabetic rats. STZ



administration led to decrease in GSH levels of serum and heart tissue, accompanied by a significant increase in MDA levels of serum and heart tissue. Also, STZ-induced DM caused to increase in serum lipid profiles.



**Figure 1:** **A.** Histological appearance was normal in control group. H-E; X40. **B.** Extensive hemorrhagic area (star) was observed in DM group. H-E; X20. **C.** Myocardial vacuolization (arrows) was detected in DM group. H-E; X40. **D.** In DM group, we also observed remarkable perinuclear vacuolization (arrows) in myocytes and hemorrhagic area (star). H-E; X40. **E.** Common inflammatory cells (arrows) were detected in DM group. H-E; X40. **F.** In some areas, loss of myofibril was observed in DM group. H-E; X40. **G-H.** In DM + Crocin group, histopathological changes decreased. H-E; X40.

Previous studies indicated that crocin treatment after STZ administration of rats ameliorated remarkably the elevated levels of GSH, as well as the decrease of lipid profiles and oxidative stress parameters, MDA, compared with untreated diabetic rats in plasma and heart tissue. These results were supported by other researchers using saffron and crocin, which recovered from oxidative damage via diabetes in rats (Plants and Karaj, 2009). We observed that these results are confirmed by variety of researches in which saffron, crocin, crocetin and safranal have protective effects against oxidative damage in the STZ diabetic rats by scavenging free radicals (Samarghandian et al., 2013).

Oxidative stress has an important role in the pathogenesis of both types of DM and the complications of diabetes (Kanter et al., 2004). Hyperglycemia leads to increase in the formation of free radicals and impair antioxidant defense systems, which give support to diabetic complications (Maritim et al., 2003b).

Clinical complications of diabetes could be prevented by reducing blood glucose level, but it is not only adequate for preventing complications. Therefore, alternative treatment methods for diabetes must be developed (Control and Group, 1994). Maritim et al. demonstrated that elevated oxidative stress caused to restrict the antioxidant defence systems in patients with DM, which might lead to insulin resistance and contribute to the development of diabetes and its complications (Maritim et al., 2003a). Accordingly, amelioration of oxidative stress by treatment with antioxidants could be an important strategy for preventing the initiation and progression of long term diabetic complications. Furthermore, insulin resistance, which results in adipocyte dysfunction, is characterized by excessive rates of lipolysis and the release of free

fatty acids (FFAs) into the plasma (McGarry, 2002). Elevated FFAs in the plasma lead to insulin resistance of hepatic and skeletal muscle and increase of hepatic triglycerides in healthy individuals (Kelley and Mandarino, 2000). The elevated hepatic triglyceride causes to increase formation of more atherogenic LDL. These results may be the mechanism of STZ-induced complications (SHAHADY, 2009).

GSH protects the tissues from oxidative damage by scavenging free radicals directly. It is also a cosubstrate for GSH-Px and a major intracellular redox system. MDA is the most important and studied parameter relating to lipid peroxidation in many diseases in recent years. MDA is used to evaluate the severity of lipid peroxidation, releasing the toxic effect of ROS, which oxidize unsaturated fatty acids in the cell membrane (Burton et al., 1984).

Dyslipidemia is defined as a disorder of lipoprotein metabolism, including lipoprotein overproduction or deficiency. Dyslipidemia may be manifested by increase of total cholesterol, LDL and TG concentrations, and decrease of HDL concentration in the blood.

After diabetic rats treated with crocin in the present study, we observed that GSH levels increased significantly both serum and heart tissue. In contrast, MDA levels decreased remarkably in serum and heart tissue. Also, total cholesterol, LDL and TG concentrations decreased remarkably, accompanied by an increase HDL levels in serum.

The results of Samarghandian et al. are confirmed by the present study (Samarghandian et al., 2013). They observed that the significant elevation in the blood glucose, MDA, nitric oxide (NO), total lipids, TG, cholesterol and reduction of GSH level, CAT and SOD activity were improved in the safranal-treated diabetic groups compared with the untreated groups, in a dose dependent manner. Our results also supported by previous studies in which saffron, crocin, crocetin and safranal had protective effects against oxidative stress due to their antioxidant properties (Xi et al., 2007).

Anti-hyperglycemic effect of saffron may be manifested by mechanism including stimulation of glucose uptake, improvement of insulin resistance, modulation of  $\beta$ -cells in pancreas to release more insulin and recovery of  $\beta$ -cells (Elgazar et al., 2013). According to these results, the protective effect of saffron on diabetic rats may occur due to its major ingredients, crocin, crocetin and safranal. These compounds might be important in modulating insulin secretion and insulin resistance and preventing diabetes complications (Plants and Karaj, 2011).

Saffron extract and its ingredients have hypolipidemic effects by modulating oxidant/antioxidant system and inhibiting pancreatic lipase activity as a competitive inhibitor (Sheng et al., 2006). Xu et al (2005) demonstrated that crocin decreased the levels of blood cholesterol, TG and LDL and increased the level of HDL in hyperlipidemic rats, feeding heavy cholesterol diet in 2 months. In addition, Samarghandian et al indicated that safranal decreased high lipid levels by modulating oxidative and nitrosive systems (Samarghandian et al., 2013). These results agreed with the present study in which crocin decreased significantly elevation of the serum lipid levels and increased the level of HDL in diabetic rats. Our findings also were confirmed by Shirali et al (Shirali et al., 2013). They indicated that crocin decreased TG, total cholesterol and LDL and elevated HDL in diabetic rats by improving insulin resistance.

The formation of ROS may lead to oxidative stress and influence the pathogenesis of myocardial infarction (Sawyer et al., 2002). ROS include free radicals such as superoxide hydroxyl, peroxy, hydroperoxy as well as non-radical species such as hydrogen peroxide and hydrochloric acid (Evans et al., 2002). When lipids react with ROS, they turn into lipids peroxides. Lipid peroxides generate several products including MDA (Raghuvanshi et al., 2007).

ROS can oxidize LDL to form ox-LDL, which is not recognized by the LDL receptor. Johansen et al reported that these oxidized lipid products could bind to specific receptor proteins or activate inflammatory proteins which produce ROS (Johansen et al., 2005). Oxidative stress plays a major role in onset of atherosclerosis. When ox-LDLs increase in blood, they can be taken into macrophages by scavenger receptors resulting in the formation of foam cell and atherosclerotic plaques (Boullier et al., 2001). The migration of ox-LDLs in vascular wall is the main reason of atherosclerosis. Saffron and its constituents can be effective on treatment of atherosclerosis by modulating lipid profiles through improvement insulin resistance, oxidant-antioxidant system and inhibition of pancreatic lipase. Furthermore, it was showed that crocetin could also prevent diabetes induced vascular complications by inhibition adhesion of leukocytes to the vascular wall (Xiang et al., 2006a).

In the present study, we observed several histopathological changes such as extensive hemorrhagic areas, cytoplasmic and perinuclear myocardial vacuolization and inflammation were found in the heart tissue of diabetic rats, but crocin treatment ameliorated heart tissue damages. Previous studies have also reported similar histopathological alterations in STZ-induced cardiac damage (Jain et al., 2010). On the other hand, in our study, crocin reduced these changes and had a therapeutic effect in diabetic cardiac damage. Jain et al. (Jain et al., 2010) reported that *Aloe vera* gel treated congestion and hemorrhage in diabetic cardiac damage. Yu et al. (Yu et al., 2013) reported that histopathological changes treated with curcumin. Dobrzynski et al. (Dobrzynski et al., 2002) found that adrenomedullin reduced glycogen accumulation in rat heart. To our knowledge, a study about available effects of crocin on STZ-induced cardiac damage in literature was not found.

The findings of one study indicated that safranal could reduce lipid peroxidation and histopathologic changes in isoproterenol-induced myocardial infarction in rats (Roya et al., 2011). Samarghandian et al. also demonstrated that safranal could prevent the formation of atherosclerosis by decreasing serum NO level (Samarghandian et al., 2013).

## Conclusion

The present study demonstrated that treatment of diabetic rats with crocin ameliorated histopathological damages in heart tissue and decreased MDA levels, accompanied by significant increase in GSH contents both serum and heart tissue. Crocin also could reduce elevated lipid profiles in serum. Our results showed that crocin might prevent diabetes induced cardiovascular complication by reduction of oxidative stress and dyslipidemia. These results support the potential efficacy of crocin for diabetes management.

**Conflict Of Interest:** Authors have no conflict of interest.

## References

1. Bast, A., Haenen, G.R. and Doelman, C.J. (1991). Oxidants and antioxidants: state of the art. *The American journal of medicine* 91, S2-S13.
2. Bhalodia, Y., Sheth, N., Vaghasiya, J. and Jivani, N. (2010). Hyperlipidemia enhanced oxidative stress and inflammatory response evoked by renal ischemia/reperfusion injury. *Int J Pharmacol* 6, 25-30.
3. Boullier, A., Bird, D.A., Chang, M.K., Dennis, E.A., Friedman, P., Gillotte-Taylor, K., Hörkö, S., Palinski, W., Quehenberger, O. and Shaw, P. (2001). Scavenger receptors, oxidized LDL, and atherosclerosis. *Annals of the New York Academy of Sciences* 947, 214-223.

4. Burton, K.P., McCord, J. and Ghai, G. (1984). Myocardial alterations due to free-radical generation. *American Journal of Physiology-Heart and Circulatory Physiology* 246, H776-H783.
5. Chen, Y., Zhang, H., Tian, X., Zhao, C., Cai, L., Liu, Y., Jia, L., Yin, H.-X. and Chen, C. (2008). Antioxidant potential of crocins and ethanol extracts of *Gardenia jasminoides* ELLIS and *Crocus sativus* L.: A relationship investigation between antioxidant activity and crocin contents. *Food Chemistry* 109, 484-492.
6. Control, D. and Group, C.T.R. (1994). The Effect of Intensive Treatment of Diabetes on the Development and Progression of Long-term Complications in Insulin-dependent Diabetes Mellitus. *Retina* 14, 286-287.
7. Cotgreave, I.A. and Gerdes, R.G. (1998). Recent trends in glutathione biochemistry—glutathione–protein interactions: a molecular link between oxidative stress and cell proliferation? *Biochemical and biophysical research communications* 242, 1-9.
8. Dobrzynski, E., Montanari, D., Agata, J., Zhu, J., Chao, J. and Chao, L. (2002). Adrenomedullin improves cardiac function and prevents renal damage in streptozotocin-induced diabetic rats. *American Journal of Physiology-Endocrinology And Metabolism* 283, E1291-E1298.
9. Elgazar, A.F., Rezaq, A.A. and Bukhari, H.M. (2013). Anti-hyperglycemic effect of saffron extract in alloxan-induced diabetic rats. *Eur J Biol Sci* 5, 14-22.
10. Ellman, G.L. (1959). Tissue sulfhydryl groups. *Archives of biochemistry and biophysics* 82, 70-77.
11. Esterbauer, H. (1993). Cytotoxicity and genotoxicity of lipid-oxidation products. *The American journal of clinical nutrition* 57, 779S-785S.
12. Evans, J.L., Goldfine, I.D., Maddux, B.A. and Grodsky, G.M. (2002). Oxidative stress and stress-activated signaling pathways: a unifying hypothesis of type 2 diabetes. *Endocrine reviews* 23, 599-622.
13. Farahmand, S.K., Samini, F., Samini, M. and Samarghandian, S. (2013). Safranal ameliorates antioxidant enzymes and suppresses lipid peroxidation and nitric oxide formation in aged male rat liver. *Biogerontology* 14, 63-71.
14. Fratelli, M., Demol, H., Puype, M., Casagrande, S., Eberini, I., Salmona, M., Bonetto, V., Mengozzi, M., Duffieux, F. and Miclet, E. (2002). Identification by redox proteomics of glutathionylated proteins in oxidatively stressed human T lymphocytes. *Proceedings of the National Academy of Sciences* 99, 3505-3510.
15. Gilbert, M.P. and Pratley, R.E. (2009). Efficacy and safety of incretin-based therapies in patients with type 2 diabetes mellitus. *European journal of internal medicine* 20, S309-S318.
16. Jain, N., Vijayaraghavan, R., Pant, S.C., Lomash, V. and Ali, M. (2010). Aloe vera gel alleviates cardiotoxicity in streptozotocin-induced diabetes in rats. *Journal of Pharmacy and Pharmacology* 62, 115-123.
17. Johansen, J.S., Harris, A.K., Rychly, D.J. and Ergul, A. (2005). Oxidative stress and the use of antioxidants in diabetes: linking basic science to clinical practice. *Cardiovascular diabetology* 4, 5.
18. Kanter, M., Coskun, O., Korkmaz, A. and Oter, S. (2004). Effects of *Nigella sativa* on oxidative stress and  $\beta$ -cell damage in streptozotocin-induced diabetic rats. *The Anatomical Record Part A: Discoveries in Molecular, Cellular, and Evolutionary Biology* 279, 685-691.
19. Kelley, D.E. and Mandarino, L.J. (2000). Fuel selection in human skeletal muscle in insulin resistance: a reexamination. *Diabetes* 49, 677-683.
20. Kolluru, G.K., Bir, S.C. and Kevil, C.G. (2012). Endothelial dysfunction and diabetes: effects on angiogenesis, vascular remodeling, and wound healing. *International journal of vascular medicine* 2012.
21. Maritim, A., Sanders, R. and Watkins, J.r. (2003a). Effects of  $\alpha$ -lipoic acid on biomarkers of oxidative stress in streptozotocin-induced diabetic rats. *The Journal of nutritional biochemistry* 14, 288-294.
22. Maritim, A., Sanders, R. and Watkins, r.J. (2003b). Diabetes, oxidative stress, and antioxidants: a review. *Journal of biochemical and molecular toxicology* 17, 24-38.
23. McGarry, J.D. (2002). Banting lecture 2001 Dysregulation of fatty acid metabolism in the etiology of type 2 diabetes. *Diabetes* 51, 7-18.
24. Militante, J.D., Lombardini, J.B. and Schaffer, S.W. (2000). The role of taurine in the pathogenesis of the cardiomyopathy of insulin-dependent diabetes mellitus. *Cardiovascular research* 46, 393-402.
25. Ohkawa, H., Ohishi, N. and Yagi, K. (1979). Assay for lipid peroxides in animal tissues by thiobarbituric acid reaction. *Analytical biochemistry* 95, 351-358.
26. Plants, A. and Karaj, I. (2009). Effects of saffron and its active constituents, crocin and safranal, on prevention of indomethacin induced gastric ulcers in diabetic and nondiabetic rats. *J. Med. Plants* 8, 30-38.
27. Plants, A. and Karaj, I. (2011). Anti-hyperglycemic effects of saffron and its active constituents, crocin and safranal, in alloxan-induced diabetic rats. *J. Med. Plants* 10, 82-89.
28. Raghuvanshi, R., Kaul, A., Bhakuni, P., Mishra, A. and Misra, M. (2007). Xanthine oxidase as a marker of myocardial infarction. *Indian Journal of Clinical Biochemistry* 22, 90-92.
29. Rahimi, R., Nikfar, S., Larijani, B. and Abdollahi, M. (2005). A review on the role of antioxidants in the management of diabetes and its complications. *Biomedicine & Pharmacotherapy* 59, 365-373.
30. Roya, M., Hosein, H., Alireza, K., Reza, P.S.M. and Soghra, M. (2011). Cardioprotective effect of safranal on isoproterenol-induced myocardial infarction in rat. *Clinical Biochemistry* 44, S359.
31. Samarghandian, S., Afshari, R. and Sadati, A. (2014). Evaluation of lung and bronchoalveolar lavage fluid oxidative stress indices for assessing the preventing effects of safranal on respiratory distress in diabetic rats. *The Scientific World Journal* 2014.
32. Samarghandian, S., Borji, A., Delkosh, M.B. and Samini, F. (2013). Safranal treatment improves hyperglycemia, hyperlipidemia and oxidative stress in streptozotocin-induced diabetic rats. *Journal of Pharmacy & Pharmaceutical Sciences* 16, 352-362.
33. Sawyer, D.B., Siwik, D.A., Xiao, L., Pimentel, D.R., Singh, K. and Colucci, W.S. (2002). Role of oxidative stress in myocardial hypertrophy and failure. *Journal of molecular and cellular cardiology* 34, 379-388.
34. Shahady, E.J. (2009). Diabetes and Cardiovascular Disease: Does Lowering Hemoglobin A1c Help or Harm? *Consultant* 49.
35. Sheng, L., Qian, Z., Zheng, S. and Xi, L. (2006). Mechanism of hypolipidemic effect of crocin in rats: crocin inhibits pancreatic lipase. *European journal of pharmacology* 543, 116-122.
36. Shirali, S., Zahra Bathaie, S. and Nakhjavani, M. (2013). Effect of Crocin on the Insulin Resistance and Lipid Profile of Streptozotocin-Induced Diabetic Rats. *Phytotherapy Research* 27, 1042-1047.
37. Srivastava, R., Ahmed, H. and Dixit, R. (2010). *Crocus sativus* L.: a comprehensive review. *Pharmacognosy reviews* 4, 200.
38. Vardi, N., Muharrem, U. and Öztürk, F. (2003). Morphological changes of rat endocrine pancreas in experimental diabetes. *Turkiye Klinikleri Journal of Medical Sciences* 23, 27.
39. Wang, C.C.L. and Reusch, J.E. (2012). Diabetes and cardiovascular disease: changing the focus from glycemic control to improving long-term survival. *The American journal of cardiology* 110, 58B-68B.



40. Wilcox, C.S. and Gutterman, D. (2005). Focus on oxidative stress in the cardiovascular and renal systems. *American Journal of Physiology-Heart and Circulatory Physiology* 288, H3-H6.
41. Xi, L., Qian, Z., Xu, G., Zheng, S., Sun, S., Wen, N., Sheng, L., Shi, Y. and Zhang, Y. (2007). Beneficial impact of crocetin, a carotenoid from saffron, on insulin sensitivity in fructose-fed rats. *The Journal of nutritional biochemistry* 18, 64-72.
42. Xiang, M., Qian, Z.-Y., Zhou, C.-H., Liu, J. and Li, W.-N. (2006a). Crocetin inhibits leukocyte adherence to vascular endothelial cells induced by AGEs. *Journal of ethnopharmacology* 107, 25-31.
43. Xiang, M., Yang, M., Zhou, C., Liu, J., Li, W. and Qian, Z. (2006b). Crocetin prevents AGEs-induced vascular endothelial cell apoptosis. *Pharmacological research* 54, 268-274.
44. Xu, G., Yu, S., Gong, Z. and Zhang, S. (2005). [Study of the effect of crocin on rat experimental hyperlipemia and the underlying mechanisms]. *Zhongguo Zhong yao za zhi= Zhongguo zhongyao zazhi= China journal of Chinese materia medica* 30, 369-372.
45. Yu, J., Peng, Y., Wu, L.-C., Xie, Z., Deng, Y., Hughes, T., He, S., Mo, X., Chiu, M. and Wang, Q.-E. (2013). Curcumin down-regulates DNA methyltransferase 1 and plays an anti-leukemic role in acute myeloid leukemia. *PloS one* 8, e55934.
46. Zheng, Y.-Q., Liu, J.-X., Wang, J.-N. and Xu, L. (2007). Effects of crocin on reperfusion-induced oxidative/nitrative injury to cerebral microvessels after global cerebral ischemia. *Brain research* 1138, 86-94.