



Rhomboid Intercostal Block for Analgesia of Multiple Rib Fractures in an Infant

Başak Altıparmak¹ , Melike Korkmaz Toker¹ , Ali İhsan Uysal² , Semra Gümüş Demirbilek¹ 

¹Department of Anesthesiology and Reanimation, Muğla Sıtkı Koçman University, Muğla, Turkey

²Department of Anesthesiology and Reanimation, Muğla Sıtkı Koçman University Training and Research Hospital, Muğla, Turkey

Cite this article as: Altıparmak B, Toker Korkmaz M, Uysal AI, Demirbilek SG. Rhomboid Intercostal Block for Analgesia of Multiple Rib Fractures in an Infant. *Turk J Anaesth Reanim.* 2021;49(5):417-419.

Abstract

Rhomboid intercostal block (RIB) is a novel plane block, which is thought to provide analgesia for both the anterior and the posterior hemithorax. Herein, we represent the successful usage of ultrasound-guided RIB on an infant patient to provide analgesia for multiple rib fractures and insertion of a chest tube. A 10-month-old, 8 kg, male infant was scheduled for insertion of a chest tube. The patient had right sided pneumothorax and multiple rib fractures from T4 to T8 after a car crush. Following induction of anaesthesia, he was placed in lateral decubitus position and RIB was performed with 8 mL 0.125% bupivacaine. A paediatric epidural catheter was placed into the interfacial plane for post-operative intermittent local anaesthetic injection as a part of multimodal analgesia with administration of intravenous paracetamol 60 mg. The post-operative pain assessment was conducted with FLACC scale at the post-operative 10th minute, 30th minute, 1st, 2nd, 6th, 12th and 24th hours, and the Face, Legs, Activity, Cry, Consolability scale score was ≤ 2 at all time-points. Ultrasound-guided RIB provided effective analgesia for insertion of a chest tube and attenuation of pain due to multiple rib-fractures in our infant patient.

Keywords: Acute pain, interfacial plane block, rhomboid intercostal block, rib fracture, post-operative pain

Introduction

Rhomboid intercostal block (RIB) is a novel plane block described by Elsharkawy et al.¹ in 2016. The authors injected methylene blue into the triangle of auscultation and assessed the spread of dye over an interfacial plane. The cadaveric examination revealed a staining of the lateral branches of the intercostal nerves from T3 to T8, medial extension to posterior primary rami and lateral extension to the axilla. Therefore, RIB was thought to provide analgesia for both the anterior and the posterior hemithorax. In the current literature, there are limited data about the clinical effect of RIB both in adult and paediatric patients.²

Herein, we represent the successful use of ultrasound-guided RIB on an infant patient to provide analgesia for multiple rib fractures and insertion of a chest tube following a car crush.

Case Presentation

A 10-month-old, 8 kg male infant was scheduled for insertion of a chest tube. The patient had right sided pneumothorax and multiple rib fractures from T4 to T8 after a car crush. Following induction of anaesthesia with intravenous (iv) propofol 3 mg kg⁻¹ and fentanyl 2 mcg kg⁻¹, a laryngeal mask airway was placed to secure the airway. Anaesthesia was maintained with Sevoflurane 2% in 2 L min⁻¹ 30% O₂-70% air mixture. The patient was placed in lateral decubitus position with the right hemithorax lying superiorly. The right arm of the patient was adducted across his chest to move the scapula laterally and open up the targeted space. RIB was performed as described previously in adult patients.¹ A high frequency linear ultrasound probe (6–12 MHz) was placed medial to the medial border of the scapula at the level of T5-T6 in oblique sagittal plane. Following identification of the trapezius and rhomboid muscles, sixth rib, intercostal muscles, pleura and lung, a 50 mm nerve block needle (Sonoplex, Pajunk Medical, Inc., Geisingen, Germany) was inserted with in-plane technique between the rhomboid and intercostal muscles. The needle position was confirmed by hydro-dissection with 0.5 mL isotonic saline solution. Then, 8 mL 0.125% bupivacaine was injected into the interfacial plane between the rhomboid muscle and the fifth rib

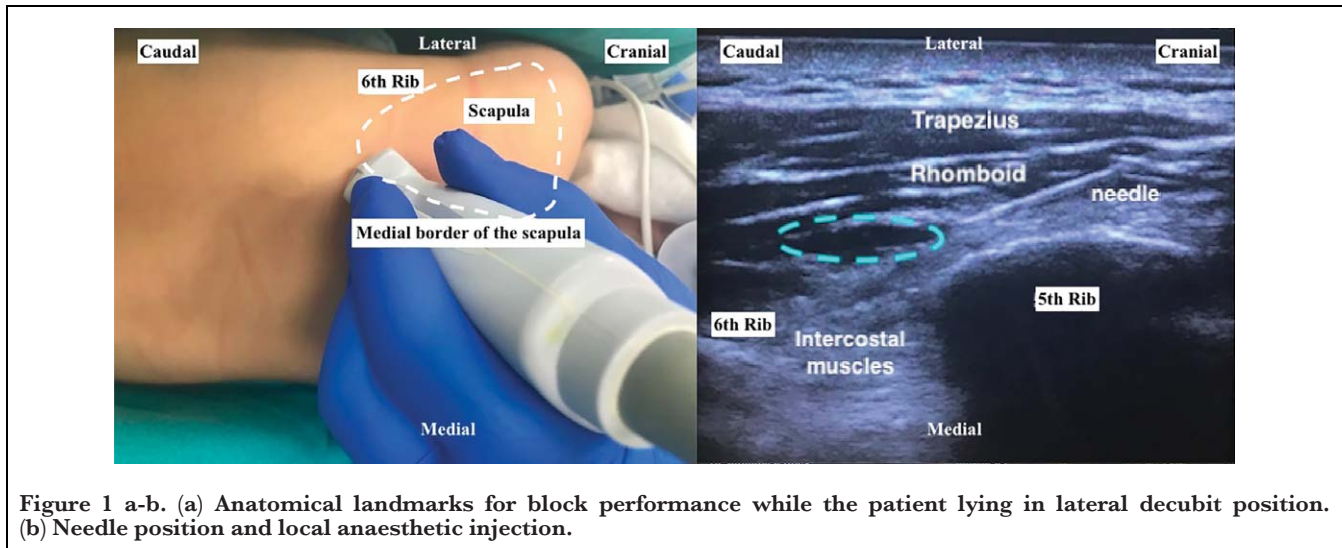


Figure 1 a-b. (a) Anatomical landmarks for block performance while the patient lying in lateral decubitus position. (b) Needle position and local anaesthetic injection.

(Figure 1). The spread of local anaesthetic solution was visualised by ultrasonography between T3 and T8. Following local anaesthetic injection, a paediatric epidural catheter was placed into the interfascial plane for post-operative intermittent local anaesthetic injection. The surgery lasted for 15 minutes and IV paracetamol 60 mg was administered for post-operative analgesia. Paracetamol dose was repeated at every 8 hour-intervals, and 4 mL 0.125% bupivacaine was injected through the catheter on the post-operative 12th hour. The post-operative pain assessment was conducted with Face, Legs, Activity, Cry, Consolability (FLACC) scale at the post-operative 10th minute, 30th minute, 1st, 2nd, 6th, 12th and 24th hours and the FLACC score was ≤ 2 at all time-points. The patient did not require additional analgesic in the first 24 hours.

Discussion

The use of ultrasound guidance has increased the performance of plane blocks in anaesthesia practice and where-upon, new block techniques have been described in the last decades. RIB seems to have a safe block technique with easily identifiable ultrasound landmarks. However, current literature comprises only one controlled study, which was

conducted in adult patients underwent breast surgery.³ Moreover, application of RIB in paediatric population was reported in a single case presentation. Ince et al.⁴ performed RIB in a 7 year-old patient and reported that RIB was effective for post-operative pain management of thoracotomy. Above case is the first infant patient to receive a RIB block, and it has a clinical importance as it suggests RIB as a safe analgesic approach in such a vulnerable patient population.

Recently, erector spinae plane (ESP) block was performed in paediatric patients for different clinical scenarios.^{5,6} De la Cuadra-Fontaine et al.⁷ successfully used continuous ESP block in a 13 kg patient for post-operative analgesia of open thoracotomy surgery. Although ESP block has been reported to be effective over several different dermatomal levels, the optimum dose and concentration of local anaesthetic solution are still controversial.

Serratus anterior plane (SAP) block could have been an alternative block approach in this case. Kurtz et al.⁸ performed ultrasound-guided SAP block in a 13-year-old male patient for effective pain control after resection of a large chest wall vascular malformation. They reported that single injection of SAP block was adequate in the pain management. SAP block provides complete analgesia of the lateral part of the chest by blocking thoracic intercostal nerves; thus, it can be used for the insertion of a chest tube. On the other hand, RIB has easily identifiable ultrasound landmarks (intercostal muscles and ribs) compared to SAP block. The block can be performed anywhere between T3 and T6. Moreover, RIB has an advantage over SAP block in placing a catheter. The injection point for RIB is usually away from the surgical site.⁹

We preferred to use a higher volume of local anaesthetic solution with a lower concentration to have a sensorial

Main Points

- Rhomboid intercostal block (RIB) is a novel plane block described by Elsharkawy et al. in 2016.
- The cadaveric examination revealed a staining of the lateral branches of the intercostal nerves from T3 to T8, medial extension to posterior primary rami and lateral extension to the axilla following an ultrasound-guided RIB block.
- RIB is a safe block technique with easily identifiable ultrasound landmarks.

blockade over a larger dermatomal area without the risk of local anaesthetic toxicity. The spread of local anaesthetic solution was visualised over five ribs.

As a conclusion, ultrasound-guided RIB provided effective analgesia for insertion of a chest tube and attenuation of pain due to multiple rib-fractures in our infant patient.

Informed Consent: Written informed consent was obtained from all participants who participated in this study.

Peer-review: Externally peer-reviewed.

Author Contributions: Concept - B.A., M.K.T., A.İ.U., M.T., S.G.D.; Design - B.A., M.K.T., A.İ.U., M.T., S.G.D.; Supervision - S.G.D.; Resources - B.A., M.T.K., A.İ.U.; Materials - B.A., M.K.T., A.İ.U., M.T., S.G.D.; Data Collection and/or Processing - B.A., M.K.T., A.İ.U., M.T.; Literature Search - B.A., M.K.T., A.İ.U., M.T.; Writing - B.A., M.K.T., A.İ.U., M.T., S.G.D.; Critical Review - B.A., S.G.D.

Conflict of Interest: The authors have no conflicts of interest to declare.

Financial Disclosure: The authors declared that this study has received no financial support.

References

1. Elsharkawy H, Saifullah T, Kolli S, Drake R. Rhomboid intercostal block. *Anaesthesia*. 2016;71(7):856-857. [\[CrossRef\]](#)
2. Ekinci M, Ciftci B, Alici HA, Ahiskalioglu A. Ultrasound-guided rhomboid intercostal block effectively manages myofascial pain. *Korean J Anesthesiol*. 2020;73:564-565. [\[CrossRef\]](#)
3. Altıparmak B, Korkmaz Toker M, Uysal AI, Dere Ö, Ugur B. Evaluation of ultrasound-guided rhomboid intercostal nerve block for postoperative analgesia in breast cancer surgery: A prospective, randomized controlled trial. *Reg Anesth Pain Med*. 2020;45(4):277-282. [\[CrossRef\]](#)
4. Ince I, Naldan ME, Ozmen O, Aydin Y. Ultrasound guided rhomboid intercostal plane block for a 7-year-old boy for post-operative thoracotomy pain. *J Clin Anesth*. 2020;60:85-86. [\[CrossRef\]](#)
5. Aksu C, Şen MC, Akay MA, Baydemir C, Gürkan Y. Erector spinae plane block vs quadratus lumborum block for pediatric lower abdominal surgery: A double blinded, prospective, and randomized trial. *J Clin Anesth*. 2019;57:24-28. [\[CrossRef\]](#)
6. Altıparmak B, Korkmaz Toker M, Uysal AI, Özcan M, Gümüş Demirbilek S. Erector spinae plane block for pain management of esophageal atresia in a preterm neonate. *J Clin Anesth*. 2019;56:115-116. [\[CrossRef\]](#)
7. De la Cuadra-Fontaine JC, Concha M, Vuletin F, Arancibia H. Continuous erector spinae plane block for thoracic surgery in a pediatric patient. *Pediatr Anaesth*. 2018;28(1):74-75. [\[CrossRef\]](#)
8. Kurtz W, Scholz S, Visoiu M. Ultrasound-guided serratus anterior plane block for effective pain control after resection of large chest wall vascular malformation in a child with phosphatase and tensin (PTEN) hamartoma tumor syndrome. *Pediatr Anaesth*. 2018;28(10):931-933. [\[CrossRef\]](#)
9. Elsharkawy H, Maniker R, Bolash R, Kalasbail P, Drake RL, Elkassabany N. Rhomboid intercostal and subserratus plane block: A cadaveric and clinical evaluation. *Reg Anesth Pain Med*. 2018;43(7):1-51. [\[CrossRef\]](#)