

of interest with any financial organization regarding the material discussed in the manuscript.

Authors' contributions.—Ying Zhang and Guangrong Dai have given substantial contributions to manuscript writing, Hai Xu, Yingge Liu, Minhui Liao and Xiaobao Zhang to manuscript revision. All authors read and approved the final version of the manuscript.

Comment on: Huang Q, Zou Y, Kong G. Hiccup, a neglected side-effect of remimazolam bolus? *Minerva Anestesiologica* 2022;88:193-4. DOI: 10.23736/S0375-9393.21.16086-9

History.—Manuscript accepted: December 2, 2021. - Manuscript revised: November 25, 2021. - Manuscript received: September 17, 2021.

(Cite this article as: Zhang Y, Dai G, Xu H, Liu Y, Liao M, Zhang X. Safety and efficacy of remimazolam compared with propofol in induction of general anesthesia: a reply. *Minerva Anestesiologica* 2022;88:194-5. DOI: 10.23736/S0375-9393.21.16169-3)

© 2021 EDIZIONI MINERVA MEDICA
Online version at <http://www.minervamedica.it>
Minerva Anestesiologica 2022 March;88(3):195-6
DOI: 10.23736/S0375-9393.21.16093-6

Peritibial fascial infiltration block and selective saphenous nerve block for postoperative analgesia of ankle fracture surgery

Over the last decade, increased availability of ultrasound (US) guidance has led to the description of in-

numerable novel fascial plane blocks. As a result, an international Delphi Consensus study was conducted to standardize nomenclature of regional anesthetic techniques of the abdominal wall, paraspinal, and chest wall regions.¹ Although some clinicians claim the daunting number of novel approaches are needless, especially easily applied techniques may provide certain advantages such as less risk of complications, less consumption of time and sources. Recently, Ekinici *et al.*² described the peritibial fascial infiltration block (PFIB) for the postoperative analgesia of tibia shaft fracture surgery. The technique simply consisted in injecting a total of 40 ml local anesthetic solution between the periosteum of tibia and fascia cruris. Postoperative analgesia of the patient was provided with intravenous (IV) tenoxicam 20 mg and an opioid rescue was not needed. The potential mechanism of PFIB was explained by the blocking of the tibial and deep peroneal nerves with local anesthetic infiltration into the compartments created by fascia cruris. In the light of this information, we decided to perform a PFIB and a selective saphenous nerve block (SNB) for the postoperative pain management of a patient with bimalleolar fracture of the ankle.

A 42-year-old, 90-kg male patient with an American Society of Anesthesiologists physical status of two, was scheduled for an emergency bimalleolar ankle fracture surgery after a car crush. He refused regional anesthesia but agreed to give consent for peripheral block procedures which would be performed after the induction of general anesthesia. Receiving the written informed consent for US-guided peripheric block procedures, anesthesia was induced with IV propofol 2 mg/kg, fentanyl 2 µg/kg, rocuronium 0.6 mg/kg and maintained with 2% sevoflurane. After endotracheal intubation, we decided to perform a US-guided PFIB and a selective saphenous nerve block. Under aseptic conditions, while the patient in supine position and lower limbs in a neutral position, a linear ultrasound probe (6-13 MHz, SonoSite-M Turbo) was placed over the

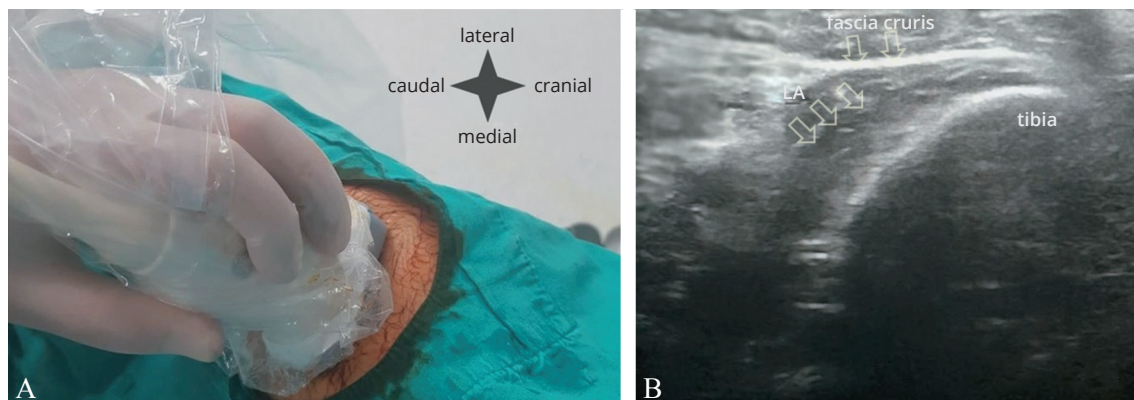


Figure 1.—A) Patient and probe position. A high-frequency 12 MHz linear US probe was placed on the tibia at approximately 10 cm proximal to the ankle joint; B) sonographic anatomy, and spread of local anesthetic. Spread of LA is seen between fascia cruris and periosteum.

LA: local anesthetic.

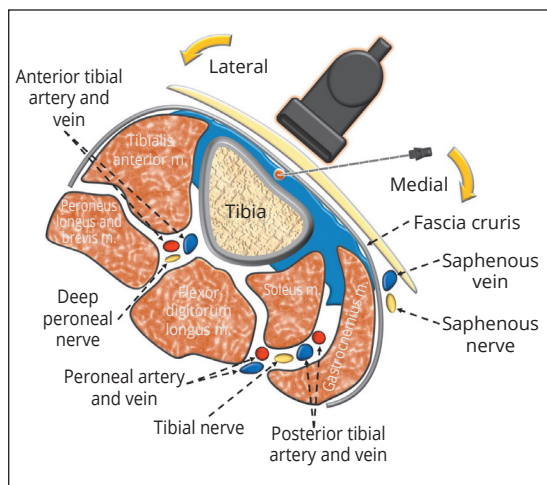


Figure 2.—The anatomical illustration of the block mechanism. Fascia cruris, tibia, deep peroneal nerve, and tibial nerve are seen. The saphenous nerve is seen out of the potential space created by fascia cruris.

tibia at approximately 10 cm proximal to the ankle joint (Figure 1A). When the periosteum and fascia cruris were visualized, a 22-G block needle was injected until the tip connected to the periosteum. Hydrodissection was performed with 2 mL of normal saline, then 30 mL of 0.25% bupivacaine were deposited between periosteum and fascia cruris (Figure 1B). Completing PFIB, the probe was moved over the medial aspect of the thigh to perform a selective SNB in the adductor canal as previously described by Manickam *et al.*³ The saphenous nerve was visualized in the short-axis (cross-sectional view) as it runs lateral to the femoral artery in the adductor canal between the sartorius and vastus medialis muscles, then 4 mL of 0.25% bupivacaine was applied. The ankle of the patient was stabilized by implant plates on both sides in approximately 150 min. He received IV dexketoprofen 50 mg and ondansetron 4 mg 15 min prior to the end of the surgery. After extubation, he was transferred to the recovery room. The postoperative pain at the 30th min was 2/10 with Numerical Rating Scale (NRS) and the patient was transferred to the surgical ward. He received iv paracetamol 1000 mg at every eight hours. His pain score remained under 4/10 and no opioid rescue was needed in the first postoperative 24 hours. In our patient, novel PFIB provided noteworthy advantages such as easy technique and performance in supine position. However, the block has a disadvantage as well. The saphenous nerve which is a purely sensorial nerve for knee and lower leg, is located out of the potential space created by fascia cruris (Figure 2). Hypothetically, PFIB is not capable of blocking SNB. Unfortunately, the proximal SNB was reported to play an important role in postoperative pain management of ankle surgery.⁴ Therefore, we additionally performed a selective SNB to cover the medial malleolus. Previously, Hoop *et al.*⁵ studied the

minimum effective volume of mepivacaine 2% needed to perform a selective SNB in adductor canal and they reported that approximately 2 mL of mepivacaine was sufficient to be effective in 95% of the patients. We performed SNB with 4 mL of 0.25% bupivacaine and the patient did not report a severe pain over medial malleolus.

In conclusion, US-guided PFIB combined with selective SNB provided a safe, easy and effective analgesia after bimalleolar fracture surgery. However, further randomized clinical trials are needed to assess its feasibility in ankle surgeries.

Basak ALTIPARMAK ¹, Bahadır CİFTCI ² *, Melike KORKMAZ TOKER ¹

¹Department of Anesthesiology and Reanimation, Mugla Sitki Kocman University, Mugla, Turkey;

²Department of Anesthesiology and Reanimation, Istanbul Medipol University, Istanbul, Turkey

*Corresponding author: Bahadır Ciftci, Department of Anesthesiology and Reanimation, School of Medicine, Mega Medipol University Hospital, Istanbul Medipol University, 34040 Bagcilar, Istanbul, Turkey. E-mail: bciftci@medipol.edu.tr

References

1. El-Boghdady K, Wolmarans M, Stengel AD, Albrecht E, Chin KJ, Elsharkawy H, *et al.* Standardizing nomenclature in regional anesthesia: an ASRA-ESRA Delphi consensus study of abdominal wall, paraspinal, and chest wall blocks. *Reg Anesth Pain Med* 2021;46:571–80.
2. Ekinci M, Kaciroglu A, Soydemir OC, Ciftci B. The effectiveness of peritibial fascial infiltration block for analgesia management after tibia fracture surgery: the description of a novel plane block. *Minerva Anestesiol* 2021;87:1269–71.
3. Manickam B, Perlas A, Duggan E, Brull R, Chan VW, Ramlogan R. Feasibility and efficacy of ultrasound-guided block of the saphenous nerve in the adductor canal. *Reg Anesth Pain Med* 2009;34:578–80.
4. Chen J, Lesser J, Hadzic A, Resta-Flarer F. The importance of the proximal saphenous nerve block for foot and ankle surgery. *Reg Anesth Pain Med* 2013;38:372.
5. Ten Hoope W, Hollmann MW, Atchabahian A, Rigaud M, Kerkhoffs GM, Lirk P, *et al.* Minimum local anesthetic volumes for a selective saphenous nerve block: a dose-finding study. *Minerva Anestesiol* 2017;83:183–90.

Conflicts of interest.—The authors certify that there is no conflict of interest with any financial organization regarding the material discussed in the manuscript.

Authors' contributions.—All authors read and approved the final version of the manuscript.

History.—Article first published online: October 28, 2021. - Manuscript accepted: October 15, 2021. - Manuscript received: August 12, 2021.

(Cite this article as: Altiparmak B, Ciftci B, Korkmaz Toker M. Peritibial fascial infiltration block and selective saphenous nerve block for postoperative analgesia of ankle fracture surgery. *Minerva Anestesiol* 2022;88:195-6. DOI: 10.23736/S0375-9393.21.16093-6)