

Pneumatization of *crista galli* in Pre-adult and Adult Stages

Neumatización de la *crista galli* en Etapas Pre Adultas y Adultas

Hasan Tetiker^{*}; Mehmet Ilkay Kosar^{*}; Nesat Çullu^{**}; Murat Sahan^{***}; Ceren Uguz Gençer^{*} & Serhan Derin^{***}

TETIKER, H.; KOSAR, M. I.; ÇULLU, N.; SAHAN, M.; GENÇER C. U. & DERIN, S. Pneumatization of *crista galli* in pre-adult and adult stages. *Int. J. Morphol.*, 34(2):541-544, 2016.

SUMMARY: The sinonasal region in humans is one of the regions that commonly shows anatomical variations. These variations can be easily diagnosed by paranasal CT evaluation. One of these variations is *Crista galli* pneumatization. In recent years, there have been opinions supporting the hypothesis that pneumatization originates from the frontal sinus. In this study, we planned to evaluate whether the presence of *Crista galli* pneumatization varied in pre-adult and adult periods. In this retrospectively designed study, 218 coronal paranasal CT images collected between 2012 and 2013 were evaluated. Patients were divided into two groups according to age under or over 18 years. In the group under the age of 18 (97 cases), pneumatization was detected in 2.1 % of samples, while in the group over the age of 18 (121 cases), *crista galli* pneumatization was observed in 15.7 % of samples. According to these results, *crista galli* pneumatization was found to increase in adulthood. Considering that the frontal sinus is in a rudimentary state at birth, it is radiographically detected first at 6 years of age, and reaches its main size in puberty, this increase in pneumatization runs parallel to the development of the frontal sinus. Consequently, this supports the opinion that *crista galli* pneumatization originates from the frontal sinus.

KEY WORDS: *Crista galli*; Paranasal sinuses; Pneumatization; Computed tomography.

INTRODUCTION

The *Crista galli* (CG), seen as a ridge in the anterior part of the anterior cranial fossa, is a thick, smooth, triangular bony process that projects upward from the cribriform plate of the ethmoid bone. The posterior border of the CG serves for the attachment of the falx cerebri. Its anterior border, short and thick, articulates with the frontal bone, and presents two small projecting wings, which are received into corresponding depressions in the frontal bone and complete the foramen cecum (Strandring, 2009). The *Crista galli* is an important structure in the sinonasal region. In humans, the sinonasal region is one of the regions that shows the most frequent anatomical variations. These variations can readily be diagnosed with paranasal computed tomography (CT) scans. Paranasal CT scanning is also valuable in studying the normal structure or variations of paranasal sinuses before endoscopic sinus surgery (Danielsen *et al.*, 2006). One of the sinuses most difficult to reach surgically is the frontal sinus, the canal of which is obliterated or narrowed most frequently by anatomical variations. One of these variations is CG pneumatization (CGP) which is often missed. *Crista galli*

pneumatization can result in infection which shows little response to medical therapy, and therefore requires endoscopic surgery as treatment (Socher *et al.*, 2013). Abnormalities narrowing the bone canals are accepted as risk factors for sinus disease. Moreover, anatomic variations in paranasal sinuses are implicated in the pathogenesis of rhinosinusitis (Fadda *et al.*, 2012).

Crista galli pneumatization and its association with adjacent structures are surgically significant. Visualization of the regional anatomy and its variations will be of help to radiologists and otorhinolaryngologists in their practice.

In recent years, there have been studies reporting that CGP originates from the frontal sinus (Basic *et al.*, 1999; Som *et al.*, 2009). Development of the frontal sinus starts at age 6 or 7 years and continues until adulthood. Parallel to this development, an increase in CGP with advancing age is expected. The purpose of this study was to assess the prevalence of CGP in pre-adults and adults.

^{*} Department of Anatomy, Mugla Sitki Kocman University, Faculty of Medicine, Mugla, Turkey.

^{**} Department of Radiology, Mugla Sitki Kocman University, Faculty of Medicine, Mugla, Turkey.

^{***} Department of Otolaryngology, Mugla Sitki Kocman University, Faculty of Medicine, Mugla, Turkey.

MATERIAL AND METHOD

This retrospective study was carried out on 218 patients (100 males and 118 females) of age 5–54 years referred for paranasal CT scanning at the Department of Radiology, Educational and Research Hospital of Mugla Sitki Koçman University, Mugla, Turkey, in the period between June 2012 and June 2013. The study was approved by the local Ethics Committee. Coronal plan paranasal CT scans suitable for examination of the anatomy and morphology of the sinonasal region were selected for study. The images obtained were categorized according to sex and age groups.

The CT images were obtained using a 16-detector row multidetector CT (MDCT) device (Siemens, Somatom Emotion, USA). The paranasal sinus CT images obtained were of 3 mm slice thickness, pitch 1, 110 kV, and 70 mAs. CT images obtained in the coronal plane and reformatted axial plane were evaluated.

The cases were divided into two age groups, namely, cases of age 18 years and over (97 cases) and cases under age 18 (121 cases). From the images obtained, the site and position of the CG were determined, and the presence of pneumatization in the CG was assessed. In the case of pneumatization, its communication with the frontal sinus was studied. The results were evaluated along with relevant studies in the literature, and their clinical implication is discussed.

RESULTS

In the present study, in total, 218 coronal plane paranasal sinus CT images were evaluated. The mean age of the patients included in the study was 24.15 years (5–54 years); for cases 18 years and over, mean age was 32.12 years, and for cases under 18, mean age was 14.21 years.

Of the 218 patients, 100 (45.9 %) were male and 118 (54.1 %) female.

Out of the 218 patients, pneumatization was detected in 21 (9.6 %). Pneumatization was present in 2.1 % (n= 2) of the group of patients under age 18 (n= 97), and in 15.7 % (n= 19) of the group of patients of age 18 and over (n= 121) (Table I). Of the 21 CGPs detected, six communicated with the right frontal sinus and 15 with the left frontal sinus (Fig. 1).

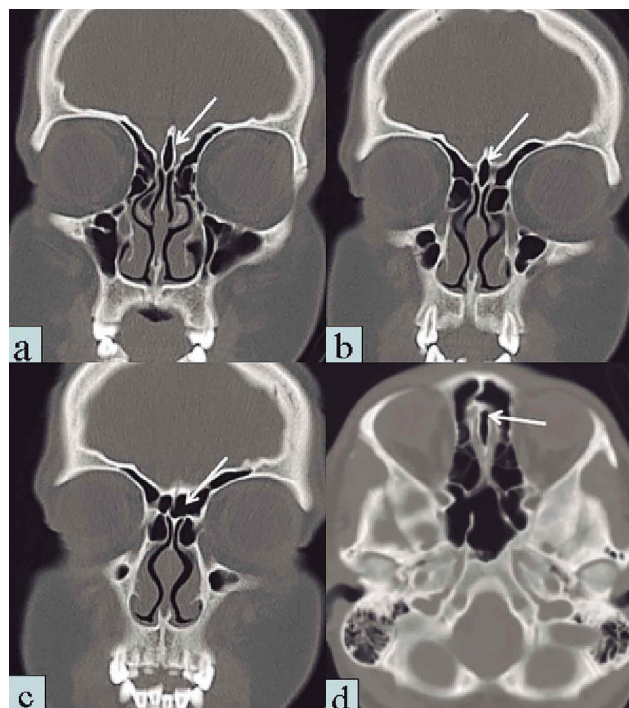


Fig. 1. Paranasal CT images from a 17-year-old patient. a, b, c: CGP in the coronal plane and its communication with the left frontal sinus. d: In the same patient, CGP in the axial plane and its communication with the left frontal sinus.

Table I. Number of crista galli pneumatizations according to age group and sex.

		Pneumatization				Total
		Yes		No		
		n	%	n	%	
<18 years of age	Male	1	2.3	42	97.7	43
	Female	1	1.9	53	98.1	54
	Total	2	2.1	95	97.9	97
≥18 years of age	Male	7	12.3	50	87.7	57
	Female	12	18.8	52	81.2	64
	Total	19	15.7	102	84.3	121

DISCUSSION

The ethmoid is ossified in the cartilage of the nasal capsule at three centers: one for the perpendicular plate, and one for each labyrinth. During the first year after birth, the perpendicular plate begins to ossify in the center. The cribriform plate is ossified partly from the perpendicular plate and partly from the labyrinths. The ethmoid bone completes its development as a single bone at about 3 years of age. Ossification of the CG is completed in the second year after birth (Strandring).

The anatomy of the sinonasal region is complex, quite variable, and frequently shows variations. In their study of 200 rhinosinusitis cases scanned by CT, Fadda *et al.*, reported anatomic variation in the sinonasal region in 140 (70 %) patients, which is a high prevalence. The rate of CGP, one of the anatomic variations, was variable. The rate of CGP has been reported as 2.4 % by Basic *et al.*, 9.3 % by Fadda *et al.*, 14.1 % by Hajjiannou *et al.* (2010), and 24 % by Arslan *et al.* (1999). In our study of coronal and reformatted axial CT scans, we found the total pneumatization rate to be 9.6 %.

Among paranasal sinuses, the frontal sinuses are the last to complete development (de Oliveira *et al.*, 2013). At birth, the frontal sinuses are not yet developed or are absent, but are generally fairly well developed between the 7th and 8th years, only reaching their full size after puberty (Scuderi *et al.*, 1993; Strandring). The frontal sinuses complete their development at ages 12–14 in females and at ages 16–18 in males (McLaughlin *et al.*, 2001).

At birth, the ethmoid sinuses are filled with fluid, and their identification is difficult (Márquez *et al.*, 2008). At age 12 years, they reach adult size and are well aerated. Some of the front group ethmoid cells develop in the anterior-superior direction, forming the frontal sinuses.

Although the CG is a structure within the ethmoid complex, there are studies reporting that its aeration is provided by the frontal sinuses (Basic *et al.*; Som *et al.*). Basic *et al.* reported the absence of CGP in 132 children under age 7, and the presence of CGP in four out of 79 children of age 7–12 and in 26 (13 %) out of 200 adults. In his study on 65 cases aged 5–16, Al-Qudah (2008) reported the absence of CGP in the 5–7 age group, and the presence of CGP in one case in the 8–12 age group and in four cases in the 12–16 age group.

In our study, we detected CGP in 2 (2.1 %) out of 97 cases aged under 18 and in 19 (15.7 %) out of 121 cases

aged 18 and over. The two cases in the former group were of age 17. Consistent with our findings, Kim *et al.* (2012) found the prevalence of CGP in 73 cases aged under 18 as 2.7% and in 745 cases aged 18 and over as 13.2%.

In our study, of the 21 CGPs detected in total, six communicated with the right frontal sinus and 15 with the left frontal sinus. Kim *et al.*, have reported that all of 100 pneumatizations, apart from one, communicated with the frontal sinus. The authors also found, that in the case with no communication with the frontal sinus, the bilateral frontal sinuses were not developed, and CGP communicated with the right ethmoid sinus (Kim *et al.*).

The findings of our study show that CGP increases in adulthood. Considering that the frontal sinus which is in a rudimentary state at birth, can be radiographically detected first at age 6, and attains its full dimensions after puberty, this increase in CGP runs parallel to the development of the frontal sinus. Consequently, this supports the opinion that CGP might originate from the frontal sinus.

CONCLUSION

The results of the present study have shown that CGP is more frequent in adulthood, and its aeration is associated with the right or left frontal sinus. We are of the opinion that these results can help radiologists and otorhinolaryngologists in their CT evaluations of anatomic variations in the sinonasal region.

TETIKER, H.; KOSAR, M. I.; ÇULLU, N.; SAHAN, M.; GENÇER C. U. & DERIN, S. Neumatización de la *crista galli* en etapas pre adultas y adultas. *Int. J. Morphol.*, 34(2):541-544-2016.

RESUMEN: La región nasosinusal en los seres humanos con frecuencia muestran variaciones anatómicas. Estas variaciones se pueden diagnosticar fácilmente mediante la evaluación por tomografía computadorizada (TC) de los senos paranasales. Una de estas variaciones es la neumatización de la *Crista galli*. En los últimos años, se ha apoyado la hipótesis de que ésta neumatización se origina en el seno frontal. En este estudio fue evaluada la presencia de neumatización de la *Crista galli* y su posible variación en los períodos pre-adultos y adultos. Se realizó un estudio retrospectivo donde se evaluaron 218 imágenes de TC coronal de senos paranasales, recogidas entre 2012 y 2013. Los pacientes fueron divididos en dos grupos según la edad, menores o mayores de 18 años. En el grupo de menores de 18 años (97 casos), se detectó neumatización en el 2,1 % de las muestras, mientras que en el grupo de mayores de 18 (121 casos), se observó neumatización de la *Crista galli* en el 15,7 % de las muestras. De acuerdo con estos

resultados, la neumatización de la *Crista galli* aumenta en la edad adulta. Teniendo en cuenta que el seno frontal se encuentra en un estado rudimentario en el nacimiento, se detecta radiográficamente a los 6 años de edad alcanzando su tamaño principal en la pubertad; este aumento de la neumatización es paralelo al desarrollo del seno frontal. En consecuencia, esto apoya la opinión de que la neumatización de la *Crista galli* se origina en el seno frontal.

PALABRAS CLAVE: *Crista galli*; Senos paranasales; Neumatización; Tomografía computadorizada.

REFERENCES

- Al-Qudah, M. The relationship between anatomical variations of the sino-nasal region and chronic sinusitis extension in children. *Int. J. Pediatr. Otorhinolaryngol.*, 72(6):817-21, 2008.
- Arslan, H.; Aydinlioglu, A.; Bozkurt, M. & Egeli, E. Anatomic variations of the paranasal sinuses: CT examination for endoscopic sinus surgery. *Auris Nasus Larynx*, 26(1):39-48, 1999.
- Basic, N.; Basic, V.; Jukic, T.; Basic, M.; Jelic, M. & Hat, J. Computed tomographic imaging to determine the frequency of anatomical variations in pneumatization of the ethmoid bone. *Eur. Arch. Otorhinolaryngol.*, 256(2):69-71, 1999.
- Danielsen, A.; Reitan, E. & Olofsson, J. The role of computed tomography in endoscopic sinus surgery: a review of 10 years' practice. *Eur. Arch. Otorhinolaryngol.*, 263(4):381-9, 2006.
- de Oliveira, A. G.; dos Santos Silveira, O.; Francio, L.A.; de Andrade Marigo Grandinetti, H. & Manzi, F. R. Anatomic variations of paranasal sinuses-clinical case report. *Surg. Radiol. Anat.*, 35(6):535-8, 2013.
- Fadda, G. L.; Rosso, S.; Aversa, S.; Petrelli, A.; Ondolo, C. & Succo, G. Multiparametric statistical correlations between paranasal sinus anatomic variations and chronic rhinosinusitis. *Acta Otorhinolaryngol. Ital.*, 32(4):244-51, 2012.
- Hajjioannou, J.; Owens, D. & Whittet, H. B. Evaluation of anatomical variation of the *Crista galli* using computed tomography. *Clin. Anat.*, 23(4):370-3, 2010.
- Kim, J. J.; Cho, J. H.; Choi, J. W.; Lim, H. W.; Song, Y. J.; Choi, S. J. & Yeo, N. K. Morphologic analysis of *Crista galli* using computed tomography. *J. Rhinol.*, 19(2):91-5, 2012.
- Márquez, S.; Tessema, B.; Clement, P. A. & Schaefer, S. D. Development of the ethmoid sinus and extramural migration: the anatomical basis of this paranasal sinus. *Anat. Rec. (Hoboken)*, 291(11):1535-53, 2008.
- McLaughlin, R. B. Jr.; Rehl, R. M. & Lanza, D. C. Clinically relevant frontal sinus anatomy and physiology. *Otolaryngol. Clin. North Am.*, 34(1):1-22, 2001.
- Scuderi, A. J.; Harnsberger, H. R. & Boyer, R. S. Pneumatization of the paranasal sinuses: normal features of importance to the accurate interpretation of CT scans and MR images. *AJR Am. J. Roentgenol.*, 160(5):1101-4, 1993.
- Socher, J. A.; Santos, P. G.; Correa, V. C. & Silva, L. C. Endoscopic surgery in the treatment of *Crista galli* pneumatization evolving with localized frontal headaches. *Int. Arch. Otorhinolaryngol.*, 17(3):246-50, 2013.
- Som, P. M.; Park, E. E.; Naidich, T. P. & Lawson, W. *Crista galli* pneumatization is an extension of the adjacent frontal sinuses. *AJNR Am. J. Neuroradiol.*, 30(1):31-3, 2009.
- Stranding, S. *Gray's Anatomy. The Anatomical Basis of Clinical Practice*. 40th ed. Philadelphia, Elsevier, 2008.

Correspondence to:
Hasan Tetiker
Department of Anatomy
Mugla Sitki Kocman University
Faculty of Medicine
48000 Mugla
TURKEY

Email: hasantetiker@gmail.com

Received: 08-07-2015
Accepted: 05-04-2016