

Stereotactic Radiosurgery and Fractionated Stereotactic Radiosurgery in Patients with Recurrent Glial Tumors

Gulnihhan EREN¹, Faruk ZORLU², Gozde YAZICI², Mustafa CENGİZ²

¹ Sıtkı Koçman University, Faculty of Medicine, Department of Radiation Oncology, Mugla

² Hacettepe University, Faculty of Medicine, Department of Radiation Oncology, Ankara, TURKEY

ABSTRACT

To evaluate stereotactic radiosurgery/fractionated stereotactic radiosurgery (SRS/fSRS) treatment outcomes of recurrent glial tumor patients who were previously treated with surgery and radiotherapy and who were not candidate for re-surgery. Thirty-one recurrent glial tumor patients treated with Cyberknife (Accuray Incorporated, Sunnyvale, CA, USA) were prospectively evaluated. The endpoints of the study were overall survival after the first diagnosis, overall survival after re-irradiation, and the parameters that affect them. Acute and chronic side effects related to the treatment were recorded. The median time between first radiotherapy and reirradiation was 26 months (range, 4-232 months). After the first radiation treatment, 27 (%87) patients relapsed in the primary radiotherapy region. A median total dose of 30 Gy (range, 18-40 Gy) was delivered in median fractions of 5 (range, 1-5 fraction) with CyberKnife. The Median follow-up was 12 months (6-37 months). The median tumor volume was 13 cc (range, 6-100 cc). The median overall survival after reirradiation was 15 months (range, 6-33 months). All the patients who developed grade 4 radionecrosis had tumor volumes greater than 25 ml. In multivariate analysis, only tumor volume (≥ 15 ml vs. < 15 ml) was found to be a statistically significant independent predictor for survival after reirradiation ($p=0.015$). Large irradiation volumes increase radionecrosis risk and decrease tumor control probability. SRS/fSRS is safe and may be an effective treatment option for selected recurrent high-grade glioma patients with small focal tumors.

Keywords: Malignant Glioma, Radiosurgery, Recurrent, Re-Irradiation, Survival

INTRODUCTION

Gliomas constitute 51% of brain tumors. The incidence of glial tumors is increasing.¹ The gold standard treatment of malignant gliomas is radiotherapy following the largest possible surgical resection. Long-term local control in high-grade malignant glial tumors is challenging due to the infiltrative nature of the disease and insensitivity to cytotoxic and targeted chemotherapy agents. Recurrence develops within an average of 1 year after the first radiotherapy treatment. Ninety percent of the relapses occur in the previously treated radiotherapy area.²

There is no standard treatment method to be applied in the case of recurrence in patients with high-grade malignant glial tumors treated with combined treatment methods such as surgery, external radiotherapy, and chemotherapy. Local control is low because chemotherapy agents are not efficient enough, the effectiveness of re-surgery is limited, and the re-irradiation causes serious irreversible damage to normal brain tissue. Most relapses occur within the previously treated radiotherapy area. For this reason, re-irradiation with conventional methods causes high toxicity.

The most dangerous of these complications is brain necrosis, which occurs approximately six months after conventional irradiation and usually causes mortality. Therefore, re-irradiation with conventional methods is not preferred in patients with high survival expectancy.³

Stereotactic radiosurgery (SRS) is a stereotactically directed very high conformal radiotherapy method in which a therapeutic dose is applied in a single fraction. Applications with high fraction doses of up to five fractions are considered as fractionated stereotactic surgery (fSRS). Less toxicity is seen with fractionated stereotactic radiosurgery than with radiosurgery.⁴ With fSRS, effective treatment can be achieved by reaching high doses in target volumes while protecting surrounding tissues. Therefore, the risk of brain necrosis is reduced in carefully selected patient groups.⁵

There are no randomized studies comparing results of surgery and stereotactic radiosurgery in recurrent or progressive malignant gliomas; however, there are prospective and retrospective studies questioning the survival advantage of stereotactic radiosurgery as salvage therapy.

In our study, patients with recurrent glial tumors who were previously treated with surgery and external radiotherapy and who were not candidate for re-surgery were treated with SRS and fSRS. These patients were prospectively followed in terms of the effectiveness, safety, and toxicity of the treatment.

MATERIAL AND METHODS

Thirty-one recurrent glial tumor patients who were treated with an image-guided, fractionated, frameless stereotactic radiosurgery technique, Cyberknife (Accuray Inc, CA, USA), were prospectively evaluated. Patients with the following characteristics were included in the study:

- 1- Pathologically diagnosed with a glial tumor
- 2- Recurrent glial tumor patients who were treated with external radiotherapy and chemotherapy after surgery and were not suitable for re-surgery
- 3- Patients between the ages of 18 and 70 years old.
- 4- Patients with adequate hematological, renal and hepatic functions (hemoglobin > 10 g/dl, absolute neutrophil count > 1500/mm³, platelet count >

100.000/mm³; serum creatinine level < 1.5 times normal values; total serum bilirubin level < 1.5 times normal values and liver function values < 3 times normal values)

5- Patients without any other known cancer disease

6- Patients with Karnofsky performance scale (KPS) value of 60 and above

Approval was taken from Hacettepe University Clinical Research Ethics Committee for this study (06-28). Age, KPS, tumor size, type of surgery, first radiotherapy dose and area, salvage surgery, re-irradiation dose, concomitant chemotherapy scheme with re-irradiation were evaluated prospectively.

The endpoints of the study were overall survival after the first diagnosis, overall survival after re-irradiation, and determination of the parameters that affect them. Acute and chronic side effects related to the treatment were recorded. Acute and late toxicities were assessed considering the RTOG (Radiation Oncology Group) / EORTC (European Organization for Research and Treatment of Cancer) toxicity scores.

Stereotactic Radiosurgery

After the patients were immobilized with a thermoplastic mask (CIVCO, Orange City, Iowa, USA), contrast-enhanced computerized tomography (CT) with a slice thickness of 1.25 mm and contrast-enhanced magnetic resonance imaging (MRI) with a slice thickness of 1 mm were performed. After fusion of CT images with MRI images, gross tumor volume (GTV) and organs at risk were delineated. The planning target volume (PTV) was created by adding the GTV a 1-3 mm margin. Fractionization schemes were decided by considering tumor size and localization. The fraction number was increased in order to reduce toxicity in patients with tumors close to critical organs such as optic chiasma and brainstem and patients with large tumors. Patients were informed about the side effects that could occur during and after the treatment, and they signed a consent form explaining these possible side effects. After SRS/fSRS all of the patients were followed up with brain MRI every three months. MRI Spectroscopy examinations were performed in cases with suspected radionecrosis.

Statistical Analysis

The follow-up period was calculated as the time between the SRS/ fSRS treatment end date and the last control date for alive patients and as the time between the SRS / fSRS treatment end date and the date of death for the patients who died. Overall survival after SRS/ fSRS was the time between the SRS / fSRS treatment end date and the last control date for alive patients; time between the SRS / fSRS treatment end date and the date of death for the patients who died. Survival analysis was evaluated by the Kaplan-Meier survival method. The results were evaluated at a 95% confidence interval and $p < 0.05$ significance level. While comparing the effects of parameters such as gender, age, type of surgery, KPS, histopathological grade, tumor volume, and chemotherapy schemes, log-rank (Mantel-cox) analysis was used. As a result of univariate analyses, statistically significant or borderline significant ($p < 0.2$) were re-evaluated in multivariate Cox regression analyses. SPSS 18.0 (Statistical Package for Social Sciences Inc., Chicago, IL) software was used for statistical analysis and graphics.

RESULTS

The follow-up period after SRS/ fSRS was median 12 months (range, 6-37 months). Our study consists of 14 female (45%) and 17 male (55%) patients. The ages of the patients ranged from 22 to 69 years, with a median age of 47 years. Tumor histopathology at the time of diagnosis is the histopathological evaluation of the tumor after the first surgery. At the initial diagnosis, 7 patients had grade 2, 8 had grade 3, and 16 had grade 4 tumors. After the first surgery and before re-irradiation, 10 patients underwent re-surgery. Thus, the final histopathological tumor grade was determined as grade 2 in 2 patients, grade 3 in 10 patients, and grade 4 in 19 patients. Patients were given a total dose of 18-40 Gy (median 30 Gy) in 1-5 fractions (median five fractions) depending on the size and location of the tumor. Reirradiation was applied to the selected patient group whose KPS values were 60 and above. The median KPS value was 70 (range, 60-80). Tumor and treatment characteristics are given in Table 1.

Table 1. Tumor and treatment characteristics

| Parameters | n (%) |
|---|---------|
| Surgery at the time of the first diagnosis | |
| Biopsy | 2 (7) |
| Partial resection | 16 (41) |
| Complete resection | 13 (52) |
| Histopathological diagnosis at the time of initial diagnosis | |
| Astrocytoma (Grade 2) | 4 (13) |
| Oligodendroglioma (Grade 2) | 3 (10) |
| Anaplastic astrocytoma (Grade 3) | 5 (16) |
| Anaplastic oligodendroglioma (Grade 3) | 3 (10) |
| Glioblastoma (Grade 4) | 16 (51) |
| Number of surgical resections | |
| 1 | 21 (68) |
| 2 | 7 (22) |
| 3 | 3 (10) |
| First radiotherapy technique | |
| 3DCRT | 25 (81) |
| IMRT | 6 (19) |
| First radiotherapy dose (Gy) | |
| 54 | 7 (22) |
| 60 | 23 (75) |
| 72 | 1 (3) |
| Last histopathological diagnosis | |
| Astrocytoma (Grade 2) | 1 (3) |
| Oligodendroglioma (Grade 2) | 1 (3) |
| Anaplastic astrocytoma (Grade 3) | 4 (13) |
| Anaplastic oligodendroglioma (Grade 3) | 6 (20) |
| Glioblastoma (Grade 4) | 19 (61) |
| Reirradiated tumor volume (median 13, range 6-100 ml) | |
| < 15 ml | 15 (48) |
| ≥ 15 ml | 16 (52) |
| Concomitant chemotherapy with SRS/fSRS | |
| Bevasizumab+irinotekan | 11 (35) |
| Temozolamide | 11 (35) |
| None | 9 (30) |

3DCRT= three-dimensional conformal radiation therapy; IMRT= intensity-modulated radiation therapy; SRS= stereotactic radiosurgery; fSRS= fractionated stereotactic radiosurgery

Univariate Analysis

The Results of Univariate Analysis for Survival after Diagnosis

Overall survival is in a wide range (16-244 months) with a median of 62 months due to differences in histopathological diagnosis. Overall survival was 49 months in the female patient group and 70

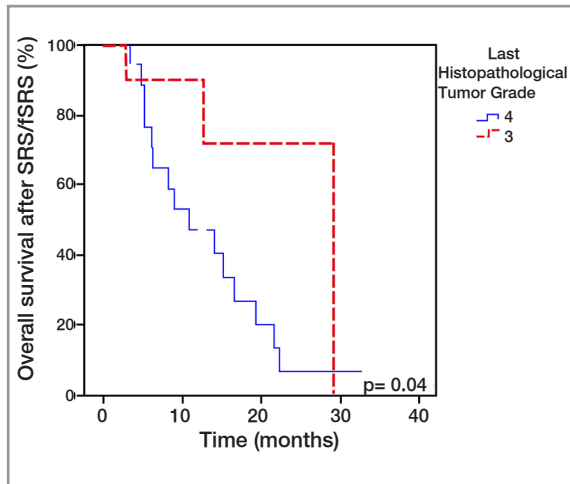


Figure 1. Kaplan-Meier curves for overall survival by the last histopathological tumor grade (4 vs. 3)

months in the male patient group ($p=0.2$). The median survival was 69 months in patients aged 45 years and under and 58 months in patients over 45 years ($p=0.2$). Overall survival was significantly lower in patients with grade 4 tumors ($p<0.001$). The median overall survival was 42 months in patients with grade 4 tumors, 127 months in patients with grade 3 tumors, and 110 months in patients with grade 2 tumors. The type of surgical resection was evaluated according to the surgery notes and postoperative imaging results. There was no significant relationship between the type of surgery at the time of diagnosis and overall survival. ($p=0.8$).

The Results of Univariate Analysis for Survival after SRS/fSRS

At a median 12-month follow-up (range, 6-37 months), overall survival after fractionated stereotactic radiosurgery was median 15 months (range, 6-33 months). 6-month and 1-year overall survival rates after SRS/fSRS were 80% and 70%, respectively. Last histopathological diagnosis before SRS/fSRS was grade 2 in 2 patients, grade 3 in 10 patients, and grade 4 in 19 patients. In this study, while the parameters affecting the overall survival after SRS / fSRS were investigated, these two patients with grade 2 tumors were not included in the univariate statistical analyzes since the clinical course of low-grade tumors differed greatly from those with higher grades.

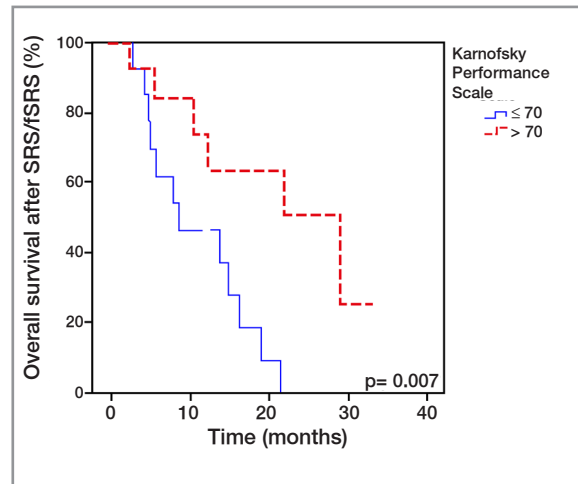


Figure 2. Kaplan-Meier curves for overall survival after SRS/fSRS by KPS values (≤ 70 vs. > 70)

Overall survival after SRS/fSRS was 11 months in patients with grade 4 tumors and 30 months in patients with grade 3 tumors ($p=0.04$) (Figure 1). Overall survival after SRS/fSRS was nine months in patients with Karnofsky Performance Score (KPS) of 70 or less, and 30 months in patients with a value above 70 ($p=0.007$) (Figure 2). Median tumor volume before SRS/fSRS was 13 cc (range, 6-100 cc). Overall survival after SRS/fSRS was 8 months in patients with a tumor volume of 15 cc and above, and 22 months in the group with less than 15 cc ($p=0.015$) (Figure 3). Survival after SRS/fSRS was 19 months in patients with peripheral lesions, 15 months in patients with deeply located tumors, and 6 months in patients with multicentric tumors. ($p=0.13$). SRS/fSRS was applied median 26 months (6-232 months) after the first radiotherapy. There was no significant relationship between survival after SRS/fSRS and the time between first radiotherapy and SRS/fSRS (< 26 , ≥ 26 months) (7 months vs. 15 months, respectively, $p=0.2$).

Multivariate Analysis

As a result of univariate analyses, statistically significant or limitedly significant (with a p value below 0.2) were re-evaluated in multivariate analyses. In multivariate analyses, overall survival after diagnosis was related to only tumor grade, while survival after SRS/fSRS was related to tumor vol-

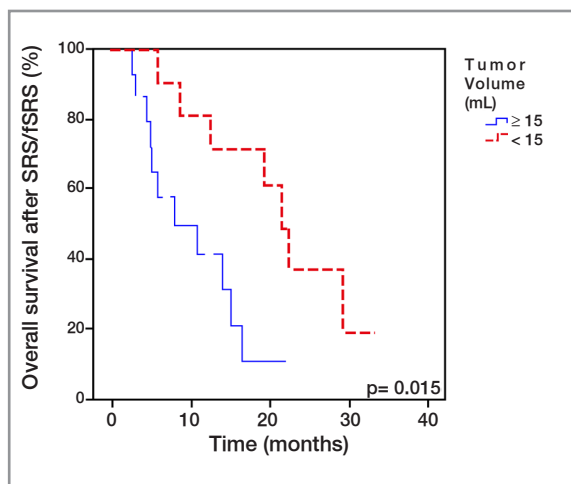


Figure 3. Kaplan-Meier curves for overall survival after SRS/fSRS by tumor volume (≥ 15 ml vs. < 15 ml)

ume ($p < 0.05$). The results of multivariate analysis for survival after diagnosis are given in Table 2, and the results of multivariate analysis for survival after SRS/fSRS are given in Table 3.

Side Effects

Acute Side Effects

During treatment, usually grade 2 and 3 side effects were seen due to reirradiation. The most common acute side effects were headache and seizure and were treated with steroids efficiently. A pre-medication mixture of steroid, antacid (H₂ receptor antagonist), and antiemetic was administered intravenously to the patients before each fraction to eliminate the acute side effects of the treatment. After the treatment was completed, the steroid dosage was lessened gradually and stopped.

Table 2. The results of multivariate analysis for survival after diagnosis

| Parameter | HR | 95%CI | p |
|----------------------------|-------|-----------|-------|
| Sex | 1.006 | 0.3-3.0 | 0.9 |
| Age (at diagnosis) | 1.3 | 0.4-4.0 | 0.6 |
| $[\leq 45, > 45]$ | | | |
| Tumor grade (at diagnosis) | | | |
| Grade 4 | 14.2 | 1.7-117.9 | 0.014 |
| Grade 3 and 2 | 1.3 | 0.2-8.3 | 0.08 |

HR= Hazard ratio

Late Side Effects

Grade 4 radionecrosis developed in 4 patients (13%) at follow-up. Apart from these patients, 3 patients (9%) died due to intra-field progression and possible radionecrosis. The distinction between progression and radionecrosis could not be clearly evaluated in a patient who died after a sudden deterioration in general condition at 12 months while being followed up with radiological and clinical stable findings in the early period after fSRS.

Pattern of Relapse

After the first radiotherapy treatment, 27 patients (87%) developed intra-field recurrence in the primary region, and 4 patients (13%) recurred outside the radiotherapy field. At the last control, 11 patients (36%) were alive, and one patient died due to chemotherapy toxicity while the disease was

Table 3. The results of multivariate analysis for survival after SRS/fSRS

| Parameter | HR | 95% CI | p |
|---|-----|----------|-------|
| KPS ($\leq 70, > 70$) | 2.3 | 0.6-9.9 | 0.24 |
| Tumor grade (4 vs 3) | 1.1 | 0.2-7.9 | 0.89 |
| Tumor volume (≥ 15 ml vs < 15 ml) | 6.9 | 1.4-33.2 | 0.015 |
| Time between first radiotherapy- SRS/fSRS | 0.9 | 0.8-1.01 | 0.61 |
| Tumor location (Multicentric, peripheral, deep) | 1.3 | 0.3-5.9 | 0.69 |

KPS= Karnofsky Performance Score; SRS= Stereotactic radiosurgery; fSRS= fractionated stereotactic radiosurgery; HR= Hazard ratio

Table 4. The relapse pattern after the first radiotherapy and re-irradiation

| | | n (%) |
|--|--------------------------------|----------|
| The relapse pattern after the first radiotherapy | Intra-field recurrence | 27 (87%) |
| | Out of field recurrence | 4 (13%) |
| The relapse pattern after SRS/fsRS | Good response to treatment | 3 (10%) |
| | Stable disease | 6 (19%) |
| | Radionecrosis | 4 (13%) |
| | Progressive disease | 17 (55%) |
| | Progression / radionecrosis | 1 (3%) |
| | could not be clearly evaluated | |

stable. According to the last control MRI results, 17 patients (55%) had progression, 3 patients had (10%) regression, 4 patients (13%) had radionecrosis, and 6 patients (19%) had stable disease. In the group with progression, 8 patients developed intra-field progression, 3 developed intra-field and external progression, 3 developed intra-field progression and possible radionecrosis, 2 patients developed leptomeningeal metastasis, and one patient developed gliomatosis cerebri. The relapse pattern after the first radiotherapy and re-irradiation is shown in Table 4.

DISCUSSION

Glial tumors are the most common central nervous system tumors in adults. Recurrence is common after intensive combined treatment methods such as surgery, external radiotherapy, and chemotherapy. Recurrence risk is over 90% in patients with high-grade gliomas.⁶ Local treatment of high-grade, recurrent gliomas is challenging due to the infiltrative spread pattern. Retrospective studies are showing an increase in survival with re-surgery in selected patient groups.⁷ Only a quarter of patients are eligible for surgery. In the study conducted by Harsh et al., survival after pre-surgery was reported as 36 weeks in grade 4 tumors and 88 weeks in grade 3 tumors.⁸

Radiotherapy is an alternative local treatment for recurrent gliomas that are not suitable for surgery. Many studies have been carried out about the outcomes of conventional radiotherapy in patients with recurrent gliomas.⁹⁻¹¹ In addition to the unsatisfactory clinical results, the rate of treatment-

related complications is high. Bauman et al. administered 34 patients with recurrent gliomas a total of 30 Gy in 10 fractions. The survival after re-irradiation was 2.8 months in the glioblastoma group and 8.5 months in the low-grade glioma group.¹⁰ In the study by Veninga et al., 42 patients were re-irradiated with a total dose of median 46 Gy (range 4-55 Gy) at 2 Gy per fraction.¹²

With the development of IMRT (intensity-modulated radiotherapy), stereotactic radiosurgery, and fractionated stereotactic radiosurgery, it has become possible to apply the highest dose to the tumor tissue while delivering the lowest dose to normal tissues around the tumor.^{13,14} Combs et al. administered 15 Gy SRS to 32 patients with recurrent glioma with a median tumor volume of 10 ml. No severe toxicity was observed, survival after SRS was found to be 10 months in this study.¹⁵ In the review of Pannulo et al., it was stated that effective local control and palliation were achieved after SRS.¹⁶ In cases where the tumor volume is large, the rate of severe toxicity increases. In the study of Hall et al., the median tumor volume was 28 ml, and survival after 20 Gy SRS was 8 months, and the rate of radiation necrosis was 14%.¹⁷ Despite the non-invasive and easy application of SRS, the risk of radionecrosis should be considered in clinical practice. In our study, SRS (20 Gy) was applied to one patient who died of progressive disease six months after SRS.

Fractionated stereotactic radiosurgery is used as salvage therapy in relatively large lesions close to critical structures such as optic chiasma, brainstem, basal ganglia, motor, and speech center. Most of these tumors are not suitable for surgery

or radiosurgery. Toxicity rates are lower with fSRS than SRS. Well circumscribed glial tumors can be controlled with fSRS.¹⁸⁻²⁰ Hudes et al. administered 20 patients a total of 24-35 Gy fSRS in 3 Gy per fraction. In this study, survival after fSRS was determined as 10.5 months and no grade 3-4 toxicity was observed.²¹ In the study of Vordermark et al., survival after SRS/fSRS was 9.3 months, and 2-year overall survival was 16% with moderate toxicity. In this study, it was stated that the strongest predictive factors for survival were tumor histology and SRS/fSRS dose (< 30 Gy vs ≥ 30 Gy).²⁰ In the literature, survival after SRS/fSRS has been indicated as 4-13 months in patients with recurrent glial tumors.¹⁸⁻²⁴ In our study, fSRS was applied to a total of 30 patients. The fractionation schemes were decided considering the tumor size and localization. In order to reduce toxicity, the fraction number was increased in patients with large tumors and tumors close to organs such as optic chiasma and brainstem. Patients were treated to a total dose of 18-40 Gy (median 30 Gy) in 1-5 fractions (median 5 fractions). Median overall survival was 15 months; 6 month and 1-year overall survival rates were 80% and 70%, respectively. These findings are consistent with the literature. Overall survival after SRS/fSRS was 11 months and 30 months in patients with histopathological grade 4 and grade 3 tumors, respectively ($p=0.04$).

Pseudoprogression is a false progression due to increased capillary permeability and damage in the blood-brain barrier due to treatments (radiotherapy and/or chemotherapy). It is seen in 30% of glioblastoma patients treated with chemoradiotherapy and 9% of patients receiving only radiotherapy.^{25,26} Diagnosis of pseudoprogression is established either by histopathological diagnosis or by determining stable disease or regression in the next MRIs. Studies are claiming that survival rates are longer in patients with pseudoprogression.^{27,28} In our study, pseudoprogression was observed in a total of 4 patients.

Radionecrosis is seen 6-12 months after radiotherapy with intense edema and can mimic the clinical course of tumor recurrence in 3-24% of the patients. Surgery may be required in cases when antiedema treatment is not sufficient.²⁹ Known risk factors for the development of radionecrosis are

total radiation dose, dose per fraction, duration of treatment, irradiated tumor volume in patients who underwent radiosurgery.^{30,31} Shepherd et al. administered 36 patients a total of 20-50 Gy fSRS in 5 Gy per fraction. Radiation necrosis was common at doses of 40 Gy, and above; 36% of the patients became dependent on steroid treatment and 6% had to undergo surgery due to radionecrosis.¹⁹ In our study, 4 patients (13%) developed grade 4 radionecrosis. The irradiated tumor volume was median 13 mL (range 6-100 ml) in the whole patient group and more than 25 ml in all patients with grade 4 radionecrosis. Although the irradiated tumor volume was 6 ml, radionecrosis was detected in a patient who was re-irradiated for a tumor in the temporal lobe. Many studies are investigating possible risk factors for radionecrosis in the temporal lobe in patients with nasopharyngeal cancer. Hot spot formation in the temporal lobe and maximum point dose are predictive factors for the development of radionecrosis.³² In the review where Mayer et al. analyzed 21 re-radiation studies, it was stated that there was an increase in radionecrosis risk when the total cumulative dose was above 100 Gy.³³ Veninga et al. observed severe long-term side effects only in patients with a cumulative bioequivalent dose above 204 Gy.¹² In our study, the median cumulative dose was 180 Gy.

There is no clear conclusion about the relationship between tumor volume and survival after re-irradiation; however, studies show better treatment outcomes in patients with small tumors. High survival rates at volumes below 30 ml, 20 ml, and 10 ml were stated in the literature.^{21,34,35} In our study, survival after SRS/fSRS was 11 months in patients with a tumor volume of 15 ml and above, and 22 months in the group with less than 15 ml. ($p=0.009$). As a result of multivariate analysis, the only statistically significant parameter affecting overall survival after SRS/fSRS was tumor volume (≥ 15 ml, <15 ml). (HR: 6.9, $p=0.015$). As stated before, in our study, all patients with fatal radionecrosis had a tumor volume of 25 ml or more. In patients with large tumor volumes, the possibility of tumor control decreases, and the rate of radionecrosis increases. SRS/fSRS should be avoided in patients with large tumor volumes, especially greater than 25 ml.

In our study, reirradiation was applied to the selected patient group whose KPS values were 60 and above. In univariate analyzes, overall survival after SRS/fSRS was 9 months in patients with KPS 70 and below and 30 months in patients with KPS above 70 ($p=0.007$). Although it was not statistically significant in multivariate analysis, survival rates were lower in the patients with KPS values below 70 (HR: 2.3, $p=0.23$). The low number of patients in our study and the fact that patients with high KPS values were recruited may have created statistical insignificance in multivariate analyzes. There are many publications with higher survival rates after SRS/fSRS in recurrent glial tumor patients with high KPS values, and our findings are consistent with the literature.^{22,36}

There is a need for randomized studies comparing the treatment results of surgery vs. stereotactic radiosurgery and/or chemotherapy treatment as salvage therapy in recurrent malignant glial tumors. The aim of salvage therapy in patients with recurrent glial tumors is to increase the quality of life as well as to prolong survival. Prospective quality of life studies should be performed in this patient group.

In conclusion, SRS/fSRS is an effective and safe treatment method for recurrent glial tumors as salvage therapy in selected patients. It can be applied successfully in patients with good general condition and well-circumscribed, small lesions. Since it is not invasive and can be completed in a relatively short time, it can provide effective palliation in progressive disease that does not respond to other treatment methods.

REFERENCES

1. Wrensch M, Minn Y, Chew T, et al. Epidemiology of primary brain tumors: current concepts and review of the literature. *Neuro Oncol* 4: 278-299, 2002.
2. Sneed PK, Gutin PH, Larson DA, et al. Patterns of recurrence of glioblastoma multiforme after external irradiation followed by implant boost. *Int J Radiat Oncol Biol Phys* 29: 719-727, 1994.
3. Bauman G, Sneed P, Wara W, et al. Reirradiation of primary CNS tumors. *Int J Radiat Oncol Biol Phys* 36: 433-441, 1996.
4. Corn BW, Curran Jr WJ, Shrieve DC, Loeffler JS. Stereotactic radiosurgery and radiotherapy: new developments and new directions *Semin Oncol* 24: 707-714, 1997.
5. Kong DS, Lee JI, Park K, et al. Efficacy of stereotactic radiosurgery as a salvage treatment for recurrent malignant gliomas. *Cancer* 112: 2046-2051, 2008.
6. Wong ET, Hess KR, Gleason MJ, et al. Outcomes and prognostic factors in recurrent glioma patients enrolled onto phase II clinical trials. *J Clin Oncol* 17: 2572-2572, 1999
7. Dirks P, Bernstein M, Muller P, Tucker W. The value of reoperation for recurrent glioblastoma. *Can J Surg* 36: 271-275, 1993.
8. Harsh GR, Levin VA, Gutin PH, et al. Reoperation for recurrent glioblastoma and anaplastic astrocytoma. *Neurosurgery* 21: 615-621, 1987.
9. Shrieve DC, Loeffler JS. Advances in radiation therapy for brain tumors. *Neurol Clin* 13: 773-793, 1995.
10. Fogh SE, Andrews DW, Glass J, et al. Hypofractionated stereotactic radiation therapy: an effective therapy for recurrent high-grade gliomas. *J Clin Oncol* 28: 3048, 2010.
11. Voynov G, Kaufman S, Hong T et al. Treatment of recurrent malignant gliomas with stereotactic intensity modulated radiation therapy. *Am J Clin Oncol* 25: 606-611, 2002.
12. Veninga T, Langendijk HA, Slotman et al. Reirradiation of primary brain tumours: survival, clinical response and prognostic factors. *Radiother Oncol* 59: 127-137, 2001
13. Kano H, Kondziolka D, Niranjan A, et al. Stereotactic radiosurgery for pilocytic astrocytomas part 1: outcomes in adult patients. *J Neurooncol* 95: 211-218, 2009.
14. Endo H, Kumabe T, Jokura H, et al. Stereotactic radiosurgery for nodular dissemination of anaplastic ependymoma. *Acta Neurochir* 146: 291-298, 2004.
15. Combs SE, Gutwein S, Thilmann C, et al. Stereotactically guided fractionated re-irradiation in recurrent glioblastoma multiforme. *J Neurooncol* 74: 167-171, 2005.
16. Pannullo SC, Fraser JF, Moliterno J, et al. Stereotactic radiosurgery: a meta-analysis of current therapeutic applications in neuro-oncologic disease. *J Neurooncol* 103: 1-17, 2011.
17. Hall WA, Djallilian HR, Sperduto PW, et al. Stereotactic radiosurgery for recurrent malignant gliomas. *J Clin Oncol* 13: 1642-1648, 1995.
18. Selch MT, DeSalles AA, Solberg TD, et al. Hypofractionated stereotactic radiotherapy for recurrent malignant gliomas. *Journal of Radiosurgery* 3: 3-12, 2000.
19. Shepherd SF, Laing RW, Cosgrove VP, et al. Hypofractionated stereotactic radiotherapy in the management of recurrent glioma. *Int J Radiat Oncol Biol Phys* 37: 393-398, 1997
20. Vordermark D, Kölbl O, Ruprecht K, et al. Hypofractionated stereotactic re-irradiation: treatment option in recurrent malignant glioma. *BMC cancer* 5: 55, 2005
21. Hudes RS, Corn BW, Werner-Wasik M, et al. A phase I dose escalation study of hypofractionated stereotactic radiotherapy as salvage therapy for persistent or recurrent malignant glioma. *Int J Radiat Oncol Biol Phys* 43: 293-298, 1999.

22. Cho KH, Hall WA, Gerbi BJ, et al. Single dose versus fractionated stereotactic radiotherapy for recurrent high-grade gliomas. *Int J Radiat Oncol Biol Phys* 45: 1133-1141, 1999.
23. Ernst-Stecken A, Ganslandt O, Lambrecht U, et al. survival and quality of life after hypofractionated stereotactic radiotherapy for recurrent malignant glioma. *J Neurooncol* 81: 287-294, 2007
24. Laing RW, Warrington AP, Graham J, et al. Efficacy and toxicity of fractionated stereotactic radiotherapy in the treatment of recurrent gliomas (phase I/II study). *Radiother Oncol* 27: 22-29, 1993.
25. De Wit M, De Bruin H, Eijkenboom W, et al. Immediate post-radiotherapy changes in malignant glioma can mimic tumor progression. *Neurology* 63: 535-537, 2004.
26. Taal W, Brandsma D, de Bruin HG, et al. incidence of early pseudo-progression in a cohort of malignant glioma patients treated with chemoirradiation with temozolomide. *Cancer* 113: 405-410, 2008.
27. Brandes AA, Franceschi E, Tosoni A, et al. MGMT promoter methylation status can predict the incidence and outcome of pseudoprogression after concomitant radiochemotherapy in newly diagnosed glioblastoma patients. *J Clin Oncol* 26: 2192-2197, 2008.
28. Yazici G, Cengiz M, Ozyigit G, et al. Hypofractionated stereotactic reirradiation for recurrent glioblastoma. *J Neurooncol* 120: 117-123, 20143.
29. Siu A, Wind JJ, Iorgulescu JB, et al. Radiation necrosis following treatment of high grade glioma- a review of the literature and current understanding. *Acta Neurochir* 154: 191-201, 2012.
30. Marks JE, Baglan RJ, Prassad SC, Blank WF. Cerebral radionecrosis: incidence and risk in relation to dose, time, fractionation and volume. *Int J Radiat Oncol Biol Phys* 7: 243-252, 1981.
31. Shaw E, Scott C, Souhami L, et al. Single dose radiosurgical treatment of recurrent previously irradiated primary brain tumors and brain metastases: final report of RTOG protocol 90-05. *Int J Radiat Oncol Biol Phys* 47: 291-298, 2000
32. Su SF, Huang Y, Xiao W-w, et al. Clinical and dosimetric characteristics of temporal lobe injury following intensity modulated radiotherapy of nasopharyngeal carcinoma. *Radiother Oncol* 104: 312-316, 2012.
33. Mayer R, Sminia P. Reirradiation tolerance of the human brain. *Int J Radiat Oncol Biol Phys* 70: 1350-1360, 2008.
34. Lederman G, Wronski M, Arbit E, et al. Treatment of recurrent glioblastoma multiforme using fractionated stereotactic radiosurgery and concurrent paclitaxel. *Am J Clin Oncol* 23: 155-159, 2000.
35. Keles GE, Lamborn KR, Chang SM, et al. volume of residual disease as a predictor of outcome in adult patients with recurrent supratentorial glioblastomas multiforme who are undergoing chemotherapy. *Journal of neurosurgery* 100: 41-46, 2004.
36. Niyazi M, Ganswindt U, Schwarz SB, et al. Irradiation and bevacizumab in high-grade glioma retreatment settings. *Int J Radiat Oncol Biol Phys* 82: 67-76, 2012.

Correspondence:**Dr. Gülnihan EREN**

Sitki Kocman Universitesi, Tıp Fakultesi
 Radyasyon Onkolojisi Anabilim Dalı
 Kötekli, Marmaris Yolu
 MUĞLA / TURKEY

Tel: (+90-539) 215 26 48

e-mail : gulnihaner84@gmail.com

ORCID:

| | |
|----------------|---------------------|
| Gulnihan Eren | 0000-0002-3315-3893 |
| Faruk Zorlu | 0000-0002-9835-4768 |
| Gozde Yazici | 0000-0002-7430-6729 |
| Mustafa Cengiz | 0000-0003-3692-8532 |