

Membranous nephropathy in a patient with ankylosing spondylitis: A rare renal manifestation or just a coincidence?

Ebru Köseoğlu Tohma¹, Feride Göğüş²

¹Department of Physical Medicine and Rehabilitation, Muğla Sıtkı Koçman University Training and Research Hospital, Muğla, Turkey

²Department of Physical Medicine and Rehabilitation, Gazi University Faculty of Medicine, Ankara, Turkey

Received: April 12, 2021 Accepted: September 16, 2021 Published online: December 10, 2021

ABSTRACT

Renal involvement in ankylosing spondylitis (AS) is uncommon and usually secondary to amyloidosis or analgesic nephropathy. A 41-year-old female patient who was diagnosed with human leukocyte antigen-B27-positive AS 16 years ago was admitted to the rheumatology outpatient clinic with pretibial and pedal edema. She had nephrotic-range proteinuria. Renal biopsy findings confirmed the diagnosis of membranous nephropathy. Extensive malignancy evaluation was negative. Edema regressed, renal functions stabilized, and proteinuria reduced within two months after immunosuppressive therapy.

Keywords: Ankylosing spondylitis, glomerulonephritis, membranous nephropathy, nephrotic syndrome, proteinuria, spondyloarthritis.

Ankylosing spondylitis (AS) is a chronic inflammatory rheumatic disease that predominantly involves the spine and sacroiliac joints. It may present with extra-articular manifestations such as uveitis, pulmonary fibrosis, cardiovascular disease, and amyloidosis.^[1,2] Renal disease in AS is rare and usually secondary to amyloidosis or analgesic nephropathy. Secondary amyloidosis, which affects about 13% of patients with AS, is the leading cause of renal impairment in AS.^[3] Glomerulonephritis is rarely associated with AS and most commonly presents as immunoglobulin (Ig) A (IgA) nephropathy, while membranous nephropathy (MN) is extremely rare in patients with AS.^[1] In the literature, there are only eight cases of this association (Table 1).

In this article, we present an uncommon case of a middle-aged female patient with coexistence of AS and MN.

CASE REPORT

A 41-year-old female patient was referred to the rheumatology outpatient clinic with pretibial and pedal edema which started 10 days before her admission. She was diagnosed with human leukocyte antigen-B27 (HLA-B27)-positive AS 16 years ago. At the time of diagnosis, she was started on sulfasalazine 2 g daily which was discontinued after three years, since she had low disease activity. She was on indomethacin 25 mg twice a day for more than 10 years. On admission, her Bath Ankylosing Spondylitis Disease Activity Index (BASDAI) score was 2.4. She had no history of uveitis, psoriasis, inflammatory bowel disease, abortus, thrombus, photosensitivity, oral aphtha or genital ulcers. She had no prior history of renal disease. Her family history was negative for any renal or systemic rheumatic disease including AS. She was smoking five cigarettes a day for 20 years. She had no history of substance or alcohol abuse.

Corresponding author: Ebru Köseoğlu Tohma, MD. Muğla Sıtkı Koçman Üniversitesi Eğitim ve Araştırma Hastanesi, Fizik Tedavi ve Rehabilitasyon Kliniği, 48000 Menteşe, Muğla, Türkiye. e-mail: ebru_koseoglu@hotmail.com

Cite this article as:

Köseoglu Tohma E, Göğüş F. Membranous nephropathy in a patient with ankylosing spondylitis: A rare renal manifestation or just a coincidence?. Turk J Phys Med Rehab 2022;68(x):i-iv.

©2022 All right reserved by the Turkish Society of Physical Medicine and Rehabilitation

This is an open access article under the terms of the Creative Commons Attribution-NonCommercial License, which permits use, distribution and reproduction in any medium, provided the original work is properly cited and is not used for commercial purposes (<http://creativecommons.org/licenses/by-nc/4.0/>).



TABLE 1
Case reports of the association of membranous nephropathy and ankylosing spondylitis

Authors	Age/sex	Associated RA or tumors	Drugs administered	Follow-up
Lemmer and Irby ^[1]	51/M	+	NSAIDs, gold salts	NA
Botey et al. ^[1]	42/M	-	Steroids	NA
Comino et al. ^[1]	35/M	+	NSAIDs, gold salts	RFT normal at 3 years
Efstratiadis et al. ^[11]	50/M	-	NSAIDs	Died, 40 days, MI
Gupta et al. ^[1]	29/M	-	NSAIDs intermittent	Partial remission 1.5 years
Kaushik et al. ^[2]	60/F	-	NSAIDs, methotrexate, etanercept	RFT normal at 1 year
Chen et al. ^[12]	44/F	-	NSAIDs	Partial remission after discontinuation of NSAID and initiation of adalimumab
Lin et al. ^[9]	64/F	Thymoma	NSAIDs	Remission after discontinuation of NSAID and initiation of steroids in six months
<i>Present case</i>	41/F	-	NSAIDs, sulfasalazine	Reduced proteinuria after discontinuation of NSAID and initiation of ACE inhibitor and cyclosporine

NSAID: Non-steroidal anti-inflammatory drug; NA: Not available; MI: Myocardial infarction; RFT: Renal function tests; ACE: Angiotensin-converting enzyme.

Her physical examination findings were normal, except for apparent bilateral pitting edema around the ankles. She had bilateral Stage 3-4 sacroiliitis on radiography. Laboratory investigations revealed severe microcytic hypochromic anemia (hemoglobin: 7.5 g/dL, mean corpuscular volume: 69.5 fL, and mean corpuscular hemoglobin concentration: 30.87 g/dL) with a low level of ferritin (6.52 ng/mL), low erythrocyte ($3.82 \times 10^3/\text{nL}$) and normal leucocyte and platelet counts, indicating iron deficiency anemia. Serum blood urea nitrogen was 9.3 mg/dL and creatinine was 0.49 mg/dL. Erythrocyte sedimentation rate was 23 mm/h and C-reactive protein level was

3.6 mg/L. She had hypoproteinemia with a total serum protein level of 5.43 g/dL and albumin of 2.4 g/dL. Urinalysis revealed Grade 1 proteinuria with no microscopic hematuria, active sediments or pyuria. The amount of 24-h urinary protein excretion was 4,531 mg. Serum total cholesterol and low-density lipoprotein cholesterol were higher than normal (330 and 238 mg/dL, respectively). Anti-nuclear antibody (ANA), hepatitis B/C and human immunodeficiency virus serology were all negative.

Indomethacin treatment was discontinued, and the patient was started on angiotensin-converting enzyme (ACE) inhibitor after which proteinuria

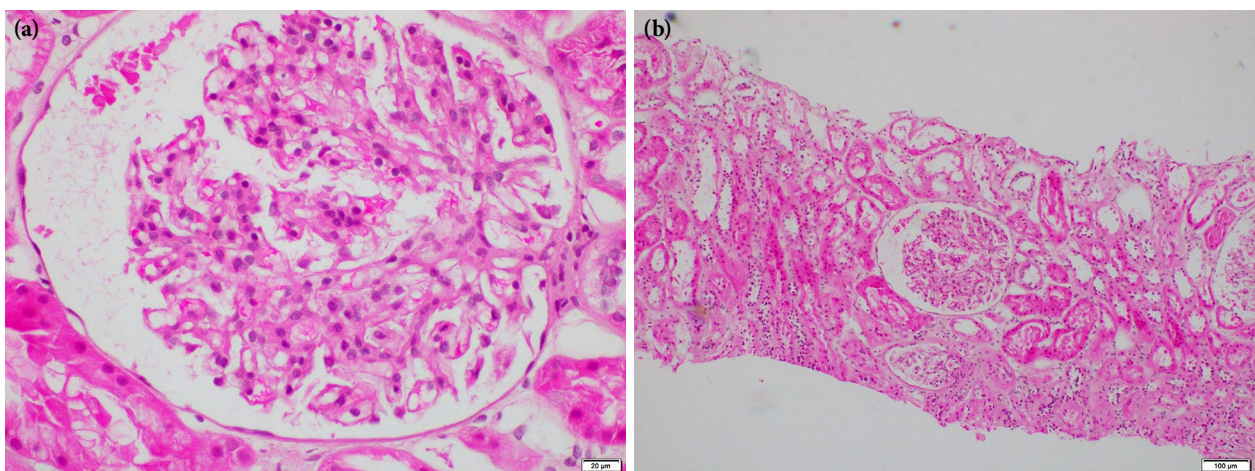


Figure 1. Renal biopsy. (a) Histological analysis shows diffuse thickening of the capillary basement membrane (H-E, $\times 400$) and (b) glomerular mesangial proliferation (H-E, $\times 100$).

reduced to 3,000 mg/24 h within one month. Rectal mucosa biopsy was negative for amyloidosis. The patient underwent a percutaneous renal biopsy for evaluation of nephrotic syndrome. Light microscopy showed 19 glomeruli with minimal diffuse thickening of basement membrane with minimal mesangial proliferation (Figure 1). Tubulointerstitial system showed no significant changes. There was no evidence of vasculitis or amyloidosis. Immunofluorescence examination showed capillary wall deposits of IgG (++) , IgA (+), and C3 (+). The histological and immunofluorescence findings confirmed the diagnosis of MN. Endoscopy, colonoscopy, posteroanterior chest radiography, mammography, abdominopelvic ultrasound, gynecologic examination, cervical smear test and transvaginal ultrasound were negative for malignancy, as well as all tumor markers. The patient was started on 0.8 g/kg/day protein diet, ramipril 2.5 mg/day, prednisolone 60 mg/day, cyclosporine 175 mg/day, acetylsalicylic acid 100 mg/day, and rosuvastatin 5 mg/day.

At two months of follow-up, pretibial edema regressed, renal functions stabilized, and proteinuria reduced to 2,577 mg/24 h. Her BASDAI score remained stable. A written informed consent was obtained from the patient.

DISCUSSION

Glomerulonephritis is a rare renal manifestation of AS of which IgA nephropathy is the most common type.^[2] Membranous nephropathy in patients with AS is uncommon; to date, only eight cases of this association have been reported in the English literature. Two of the previously reported cases had concomitant rheumatoid arthritis and was receiving gold salts, which are known to cause secondary MN. The sixth case was on etanercept to which development of MN was attributed.^[2] One case was on steroids, while all the other patients, including the present case, were on non-steroidal anti-inflammatory drugs (NSAIDs).

It is well known that NSAIDs lead to nephrotoxicity secondary to interstitial nephritis (proteinuria and/or acute renal failure) or renal papillary necrosis. There are MN cases associated with all NSAIDs including selective cyclooxygenase-2 inhibitors, which suggests that renal damage may be mediated through cyclooxygenase inhibition. In most cases, cessation of the drug results in rapid and complete remission of proteinuria without immunosuppressive therapy, confirming the pathogenic role of NSAIDs in MN.^[1,4,5] A causal relationship between the NSAIDs

and MN seems likely in our case, since she was on indomethacin daily for more than 10 years. However, there was a decrease of about 30% in proteinuria following discontinuation of indomethacin, which may be considered a partial amelioration. Furthermore, initiation of an ACE inhibitor, cyclosporine, and steroid might have contributed to the reduction of proteinuria and regression of edema, as well.

Sulfasalazine-related renal failure is extremely rare and is usually associated with acute or chronic interstitial nephritis. In the literature, there are three case reports of sulfasalazine-induced nephrotic syndrome of which histological diagnoses revealed minimal change nephropathy. All these cases were on daily sulfasalazine therapy for more than one year or on current therapy, when renal failure occurred.^[6-8] Our patient had no disease-modifying drug history other than sulfasalazine which was continued for three years following the time of diagnosis, indicating that she was not on sulfasalazine for more than 10 years. Furthermore, her histological diagnosis was MN with no interstitial changes. Therefore, it seems highly unlikely that nephrotic syndrome is related to sulfasalazine.

Membranous nephropathy may be associated with malignancy, particularly with solid organ cancers in the lung, colon, breast, prostate or uterus. About 10% of patients with MN have malignancy concurrently with renal biopsy or are diagnosed with malignancy within a year after.^[4] In the present case, we ruled out the presence of malignancies, viral infections, hematological and autoimmune diseases, including lupus nephritis with a detailed clinical and laboratory evaluation. The clinical picture and renal biopsy findings also excluded the diagnoses of lupus nephritis or vasculitis.

All the reported patients with AS and MN association, including our case, were established AS patients with long disease durations. Of these eight cases, five were males and seven were HLA-B27-positive, whereas HLA-B27 status was unknown in one case. It is noteworthy that disease activity of our case, which was measured by BASDAI and acute phase reactants, was low. She had no active disease on admission, suggesting that there is no correlation between MN and disease activity. Of the other cases in the literature, disease activity (BASDAI score) was documented only in one case, showing an active disease, contrary to our case.^[9]

Antigens associated with AS pathogenesis possibly reach the subepithelial capillary basement membrane

and bind to specific antibodies forming subepithelial immune complexes of MN.^[1] There are several reports indicating differences in the distribution pattern of glomerular IgG subdeposits among idiopathic and secondary MN. A predominant deposition of IgG4 is typical for idiopathic MN, while deposition of other subclasses is reported in secondary MN, such as lupus nephritis, NSAIDs, or malignancy-related MN. Subclass deposition of IgG or phospholipase A2 receptor (PLA2R) antibodies, a recently discovered specific marker of idiopathic MN, could not be analyzed in the present case, as they were not among the laboratory tests of our hospital. However, the presence of mesangial proliferation indicates secondary nature of MN.^[4,10]

There may be a causal relationship between NSAID use and MN, since our patient had no other medical history than a prolonged daily usage of indomethacin. However, discontinuation of the drug did not lead to complete remission of nephrotic syndrome or edema. On the other hand, it is of interest that majority of the cases in the literature (7/8) were on NSAIDs. Considering the autoimmune nature of the disease, MN may also be associated with AS in the present case. However, since the association of AS and MN is extremely rare, for this case, it remains ambiguous whether MN is secondary to AS or a coincidental finding.

In conclusion, we present an uncommon case of MN in a middle-aged female patient with established AS. To distinguish MN from renal impairment related to NSAIDs or secondary amyloidosis is crucial to initiate convenient immunosuppressive therapy and to prevent renal damage. Whether there is a causal relationship between MN and AS still remains to be a matter of debate. We believe that, regardless of disease activity, it is essential to monitor renal function at regular intervals in patients with AS.

Declaration of conflicting interests

The authors declared no conflicts of interest with respect to the authorship and/or publication of this article.

Funding

The authors received no financial support for the research and/or authorship of this article.

REFERENCES

1. Gupta R, Sharma A, Arora R, Dinda AK, Gupta A, Tiwari SC. Membranous glomerulonephritis in a patient with ankylosing spondylitis: A rare association. *Clin Exp Nephrol* 2009;13:667-70.
2. Kaushik P, Rahmani M, Ellison W. Membranous glomerulonephritis with the use of etanercept in ankylosing spondylitis. *Ann Pharmacother* 2011;45:e62.
3. Strobel ES, Fritschka E. Renal diseases in ankylosing spondylitis: Review of the literature illustrated by case reports. *Clin Rheumatol* 1998;17:524-30.
4. Moroni G, Ponticelli C. Secondary membranous nephropathy. A narrative review. *Front Med (Lausanne)* 2020;7:611317.
5. Radford MG Jr, Holley KE, Grande JP, Larson TS, Wagoner RD, Donadio JV, et al. Reversible membranous nephropathy associated with the use of nonsteroidal anti-inflammatory drugs. *JAMA* 1996;276:466-9.
6. Alivanis P, Aperis G, Lambrianou F, Zervos A, Paliouras C, Karvouniaris N, et al. Reversal of refractory sulfasalazine-related renal failure after treatment with corticosteroids. *Clin Ther* 2010;32:1906-10.
7. Molnár T, Farkas K, Nagy F, Iványi B, Wittmann T. Sulfasalazine-induced nephrotic syndrome in a patient with ulcerative colitis. *Inflamm Bowel Dis* 2010;16:552-3.
8. Dwarakanath AD, Michael J, Allan RN. Sulphasalazine induced renal failure. *Gut* 1992;33:1006-7.
9. Lin L, Zhao L, Huo B, Zheng L, Yu R, Li W, et al. Membranous nephropathy and thymoma in a patient with ankylosing spondylitis: A case report. *Medicine (Baltimore)* 2020;99:e20111.
10. Ponticelli C, Glassock RJ. Glomerular diseases: Membranous nephropathy--a modern view. *Clin J Am Soc Nephrol* 2014;9:609-16.
11. Efstratiadis G, Tsiaousis G, Leontini M, Gionanlis L, Papagianni A, Memmos D. Membranous glomerulonephritis complicating ankylosing spondylitis. *Clin Nephrol* 2006;66:75-6.
12. Chen R, Li F, Xie Q, Xue J, Lai L, Liu S, et al. Membranous nephropathy in a patient with ankylosing spondylitis: A case report. *Medicine (Baltimore)* 2017;96:e8201.