

An Unusual Clinical Presentation of Papillary Fibroelastoma Case Ending with Sudden and Unexpected Death of a Child

Beklenmeyen Ani Çocuk Ölümü ile Sonuçlanmış Sıra Dışı Bir Klinik Başvurusu Olan Bir Papiller Fibroelastom Olgusu

¹Yasemin BALCI^a, ²Melike ERBAŞ^b

^aDepartment of Forensic Medicine, Muğla Sıtkı Koçman University Faculty of Medicine, Muğla, TÜRKİYE

^bMuğla Council of Forensic Medicine, Muğla, TÜRKİYE

ABSTRACT Papillary fibroelastoma is one of the rare benign cardiac tumors; that stays asymptomatic and is usually found unintentionally during routine transthoracic and/or transesophageal echocardiographic (EKO) examinations. Papillary fibroelastomas arising from the left cardiac valves may usually cause systemic embolism and the right sided papillary fibroelastomas may cause recurrent pulmonary embolism. Papillary fibroelastomas arising from the aortic valves may cause coronary embolism that leads to myocardial infarction and sudden death. We present in this case study a sudden and unexpected death of a child who ate pears after dinner, fainted, started vomiting and died suddenly and unexpectedly despite all medical interventions. The case was taken to Muğla State Hospital by her family; but lost her life despite all medical interventions. In the autopsy of the case performed with the suspicion of intoxication the papillary fibroelastoma of the mitral valve was detected in the autopsy and concluded as a cause of death.

Keywords: Sudden cardiac death; papillary fibroelastoma; autopsy

ÖZET Papiller fibroelastom nadir görülen benign kardiyak tümörlerdendir. Papiller fibroelastoma, asemptomatik bir seyir izlemekte ve genellikle rastlantısal olarak rutin transtorakal ve/veya transözafagial ekokardiyografik (EKO) incelemede saptanmaktadır. Sol kalp kapaklarındaki papiller fibroelastomlar sistemik embolilere, sağ taraflı papiller fibroelastomlar ise tekrarlayan pulmoner embolilere neden olabilmektedir. Aortik kapak kaynaklı papiller fibroelastomlar koroner embolilere sebep olarak myokardiyal enfarkt ve ani ölümlere sebep olabilmektedirler. Bu çalışmada, akşam yemeğinden sonra armut yiyen, ardından bayılan, kusmaya başlayan ve ani ve beklenmedik şekilde ölen bir çocuk olguyu sunuyoruz. Olgu ailesi tarafından Muğla Devlet Hastanesine götürülmüş; ancak yapılan tıbbi müdahaleye rağmen hayatını kaybetmiştir. Olgunun entoksikasyon şüphesi ile yapılan otopsisinde mitral kapağın papiller fibroelastomu saptanmıştır ve ölümün nedeni olduğu düşünülmüştür.

Anahtar Kelimeler: Ani kardiyak ölüm; papiller fibroelastom; otopsi

Papillary fibroelastomas arising from the left cardiac valves may usually cause systemic embolism and the right sided papillary fibroelastomas may cause recurrent pulmonary embolism.¹⁻³ Depending on the side obstructed by a thrombus or the localization of the tumor, patients may present with findings of pulmonary embolism or with findings of cerebral embolism; papillary fibroelastomas arising from the aortic valves may cause coronary

embolism that leads to myocardial infarction and sudden death.^{3,4}

CASE REPORT

A 7-year-old girl after having dinner with her parents, sister and friends eats pears of their own garden, gets sick and starts vomiting. Family takes her to the Muğla State Hospital but she dies despite all medical interventions.

Correspondence: Melike ERBAŞ

Muğla Council of Forensic Medicine, Muğla, TÜRKİYE/TÜRKİYE

E-mail: dr.melikeerbas@gmail.com



Peer review under responsibility of Türkiye Klinikleri Journal of Forensic Medicine and Forensic Sciences.

Received: 14 Jun 2021

Received in revised form: 26 Oct 2021

Accepted: 01 Nov 2021

Available online: 10 Nov 2021

2619-9459 / Copyright © 2022 by Türkiye Klinikleri. This is an open access article under the CC BY-NC-ND license (<http://creativecommons.org/licenses/by-nc-nd/4.0/>).

AUTOPSY FINDINGS

In the external examination, the body was 126 cm in height belonging to a 7 year old brunette girl having brown eyes. There were no pathological signs in the external examination except the foaming at the mouth, and an injection mark on the right antecubital fossa.

On examination of the head, there was a bruising 1x1 cm in size at the frontal region under the scalp and no fractures at the calvarium. The brain and brainstem weighed 1,222 g. The brain and brainstem were morphologically normal and there was no pathology seen at the dissections except a slight prominence of vessels.

On examination of mouth and neck structures, there was a region of hematoma 1x0.5 cm in size at the inlet of the esophagus that was assumed to be due to the medical interventions and there was no other morphological pathology of the organs, soft tissues, bone and cartilages of this region.

On examination of the thorax, the left third and the right second, third and fourth ribs were seen as fractured from the mid-clavicular line and the sternum was also seen as fractured at the level of third inter-costal region and all these fractures were assumed to be due to resuscitation. The lungs were seen bilaterally edematous and the dissections of the lungs were evaluated bilaterally as severely edematous and the scene of intense foaming was detected. Right lung weighed 276 g, left lung weighed 252 g. The pericardium and the pericardial cavity were normal but the general size of the heart was bigger than normal. There was a tumor seen like a milimetric bunch of grapes on the valve where it attaches to the papillary muscle [Figure 1](#). The myocardium was morphologically normal. The sizes of the heart valves and the thickness of the right and left myocardial walls were in normal ranges. The measurements recorded were as follows; aortic valve: 3.9 cm, pulmonary valve: 4.5 cm, mitral valve: 6 cm, tricuspid valve: 8 cm, left ventricular wall: 0.7 cm, right ventricular wall: 0.2 cm. The heart weighed 134 g.

On examination of the abdomen, the whole abdominal organs were in their anatomical positions and all of them were morphologically normal. No

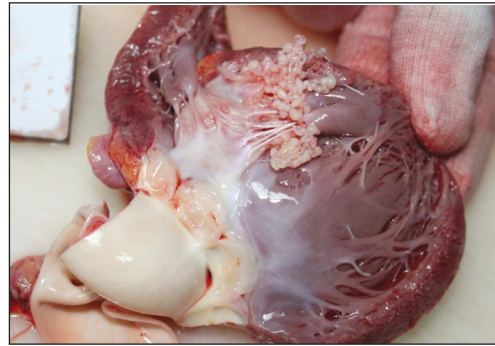


FIGURE 1: Appearance of the papillary fibroelastomas on the mitral valve where it attaches to the papillary muscle.

pathology was detected at the dissections of the organs. The liver weighed 744 g. The spleen weighed 72 g. The kidneys bilaterally were seen morphologically normal and no pathology was detected at their dissections, the capsule, pelvis, medulla, corticomedullary borders and cortex of both kidneys were morphologically normal. The right kidney weighed 68 g, the left kidney weighed 74 g.

In histopathologic examinations; in the samples of cardiac tissues, papillary fibroelastoma was reported on the mitral valve. Severe intraalveolar hemorrhage and edema, slight peribronchial lymphocytic infiltration with a little focal pneumonic infiltration focus were detected in tissues of the lung. In toxicological examinations, there was nothing found except atropine presumably used during resuscitation.

It was concluded that the sudden death of the 7 year old girl after fainting and vomiting was due to the papillary fibroelastoma of the mitral valve and possible complications related with the tumor.

Necessary approval was obtained from Council of Forensic Medicine Approval Committee for Scientific Studies by the decision dated Feb 02 2020 and numbered 21589509/2020/183 also the criteria of Helsinki Declaration were taken into consideration.

DISCUSSION

Papillary fibroelastoma incidence in autopsy series is reported to be between 0.0017-0.33%.² It was detected in one case among 2,534 cases autopsied in Muğla Directorate of Forensic Medicine Institute between the years of 2013 and 2018.

Mitral fibroelastomas are usually located at the atrial side of the valve. It should be differentiated from organized mobile thrombus and pedunculated myxoma.⁵ Papillary fibroelastomas usually stay asymptomatic and are usually detected unintentionally during echocardiographic examinations for various reasons. There is no specific clinical or laboratory sign that may indicate fibroelastomas. The risk of systemic embolism is higher in tumors over 1 cm in size. In contrast with the papillary fibroelastomas of the aortic valves, the risk of systemic embolization is higher for papillary fibroelastomas of the mitral valves and these mitral papillary fibroelastomas may cause transient ischemic attack, stroke and unilateral blindness. The papillary fibroelastomas of aortic valves may cause coronary embolism leading to myocardial infarction or sudden death.^{3,4,6} The presented case in our case presentation was found to have a papillary fibroelastoma on mitral valve.

In asymptomatic fibroelastoma cases, warfarin or antithrombotic therapies may be used to avoid thromboembolization and also the risks of myocardial infarction and sudden death; but even if asymptomatic, the researchers conclude on surgically excision of the tumor for prevention.^{4,6}

Canbay et al. reported a case, who was nearly followed for 20 years and gone under coronary artery bypass surgery that ended up with the excision of a fibroelastoma arising from the papillary muscle chordae on the anterior leaflets of the mitral valve.¹

In United States of America, a 70-years-old woman was reported who died suddenly 2 weeks later after a surgical procedure for her knees. In the autopsy, it was recognized that the fibroelastoma of the aortic valve obstructed the right coronary ostium.⁷ A 75-years-old woman was reported who died shortly after representing with sudden hypotension and back radiating chest pain thought to be due to aortic dissection. In the autopsy, obstruction of the left coronary artery outlet by a fibroelastoma was seen.⁸ Similarly a 68-years-old Japanese male was reported

who collapsed suddenly and died. In the autopsy, it was recognized that the fibroelastoma arising from the aortic valve occluded the right coronary artery causing embolization and myocardial infarction.⁹

The case we presented in this study was a 7-year-old girl who ate pears after dinner and sometime later got sick, fainted and started vomiting and died. According to the anamnesis, it was thought that the case was foreign body aspiration or intoxication; but there were no findings to support these ideas. It was concluded that; according to the autopsy and the histopathological findings on tissues of the lungs were supporting the diagnosis of acute pulmonary embolism and the death cause was papillary fibroelastoma and possible complications related with it. The case worth to be presented for its unusual presentation that requires differential diagnosis for sudden and unexpected deaths in children.

Acknowledgements

All necessary permissions were taken from the Council of Forensic Medicine, İstanbul.

Source of Finance

During this study, no financial or spiritual support was received neither from any pharmaceutical company that has a direct connection with the research subject, nor from a company that provides or produces medical instruments and materials which may negatively affect the evaluation process of this study.

Conflict of Interest

No conflicts of interest between the authors and / or family members of the scientific and medical committee members or members of the potential conflicts of interest, counseling, expertise, working conditions, share holding and similar situations in any firm.

Authorship Contributions

Idea/Concept: Yasemin Balci; **Design:** Yasemin Balci; **Control/Supervision:** Melike Erbaş; **Data Collection and/or Processing:** Melike Erbaş; **Analysis and/or Interpretation:** Yasemin Balci; **Literature Review:** Yasemin Balci; **Writing the Article:** Yasemin Balci; **Critical Review:** Yasemin Balci; **References and Fundings:** Melike Erbaş; **Materials:** Melike Erbaş.

REFERENCES

1. Canbay Ç, Öztaş DM, Güler E, Karatay H, Babur Güler G, Arasan O, et al. Mitral kapak kaynaklı papiller fibroelastom [Papillary fibroelastoma of the mitral valve]. *Türkiye Klinikleri J Cardiovasc Sci.* 2016;28(3):118-22. [[Crossref](#)]
2. Öz K, Aktürk İF, Ulukan MÖ, Ersoy B, Ereğ E. An unusual presentation of a cardiac papillary fibroelastoma: A case report. *Türk Gogus Kalp Dama.* 2014;22(4):826-9. [[Crossref](#)]
3. Ikegami H, Andrei AC, Li Z, McCarthy PM, Malaisrie SC. Papillary fibroelastoma of the aortic valve: Analysis of 21 cases, including a presentation with cardiac arrest. *Tex Heart Inst J.* 2015;42(2):131-5. [[Crossref](#)] [[PubMed](#)] [[PMC](#)]
4. Wang Y, Wang X, Xiao Y. Surgical treatment of primary cardiac valve tumor: Early and late results in eight patients. *J Cardiothorac Surg.* 2016;11:31. [[Crossref](#)] [[PubMed](#)] [[PMC](#)]
5. Hakim FA, Aryal MR, Pandit A, Pandit AA, Alegria JR, Kendall CB, et al. Papillary fibroelastoma of the pulmonary valve-a systematic review. *Echocardiography.* 2014;31(2):234-40. [[Crossref](#)] [[PubMed](#)]
6. Kuralay E. Papillary fibroelastoma located on tricuspid valve. *Türk Gogus Kalp Dama.* 2015;23(1):137-9. [[Crossref](#)]
7. Prahlow JA, Barnard JJ. Sudden death due to obstruction of coronary artery ostium by aortic valve papillary fibroelastoma. *Am J Forensic Med Pathol.* 1998;19(2):162-5. [[Crossref](#)] [[PubMed](#)]
8. Zull DN, Diamond M, Beringer D. Angina and sudden death resulting from papillary fibroelastoma of the aortic valve. *Ann Emerg Med.* 1985;14(5):470-3. [[Crossref](#)] [[PubMed](#)]
9. Takada A, Saito K, Ro A, Tokudome S, Murai T. Papillary fibroelastoma of the aortic valve: A sudden death case of coronary embolism with myocardial infarction. *Forensic Sci Int.* 2000;113(1-3):209-14. [[Crossref](#)] [[PubMed](#)]