

## INTESTINAL OBSTRUCTION DEVELOPED DUE TO INTESTINAL INTRAMURAL HEMATOMA BECAUSE OF WARFARIN OVERDOSE

GULEN BEDIA<sup>1</sup>, KUCUKDAGLI OKKES TAHA<sup>1</sup>, BEYDILLI HALIL<sup>2</sup>, SONMEZERTAN<sup>1</sup>, SOGUT ÖZGÜR<sup>1</sup>, SERINKEN MUSTAFA<sup>3</sup>

<sup>1</sup>Bezmialem Vakif University Medical Faculty, Department of Emergency Medicine - <sup>2</sup>Mugla Sıtkı Kocman University Medical Faculty, Department of Emergency Medicine - <sup>3</sup>Pamukkale University Medical Faculty, Department of Emergency Medicine, Istanbul, Turkey

### ABSTRACT

*Oral anticoagulant therapy with warfarin is commonly used to prevent thromboembolic events in high risk patients. A spontaneous intramural intestinal hematoma is a rare complication of the anticoagulant therapy. Small intestinal obstruction, which is developed due to intramural hematoma, is an even more rarely encountered state. Early diagnosis is very important since it responds to the treatment very well without requiring operation on the most patients. In our unstable case, although there is no risk factor, INR was reduced quickly by using prothrombin complex concentrate (Factor II/VIII/IX); this raised the possibility of patient's treatment without complication.*

**Key words:** Intramural hematoma, warfarin, overdose, prothrombin complex concentrate.

*Received November 30, 2014; Accepted May 02, 2015*

### Introduction

Vitamin K antagonists (warfarin, phenprocoumon, acenocoumarol) are used commonly for prophylactic and therapeutic. Oral anticoagulant therapy with warfarin is chiefly used to prevent thromboembolic events in patients at high risk<sup>(1)</sup>. The degree of anticoagulation is influenced by many factors so that patients must be monitored frequently to assess the potential adverse effects related to treatment. Because bleeding is the most important complication of anticoagulant therapy. This problem of over anticoagulation may present in uncommon ways. Anticoagulant-dependent spontaneous intramural hematoma of the small intestine is a very rare complication<sup>(2)</sup>. An incidence of one in 2500 patients receiving warfarin was reported<sup>(3,4)</sup>. The incidence higher in male and average at presentation is 58 years<sup>(5)</sup>. INR is used as an indication of anticoagulant effect, such that values >3 are associated with increased incidence

of bleeding. The first symptom of intramural hematoma of the small intestine is abdominal pain accompanied by nausea, and vomiting; occasionally it can occur along with gastrointestinal bleeding. Acute abdominal symptoms can develop in cases of total intestinal obstruction and ischemia. Conservative treatment is recommended instead of surgical treatment as first line therapy. Surgery or percutaneous drainage should be considered for patients with persistent obstruction or expanding hematomas<sup>(6)</sup>.

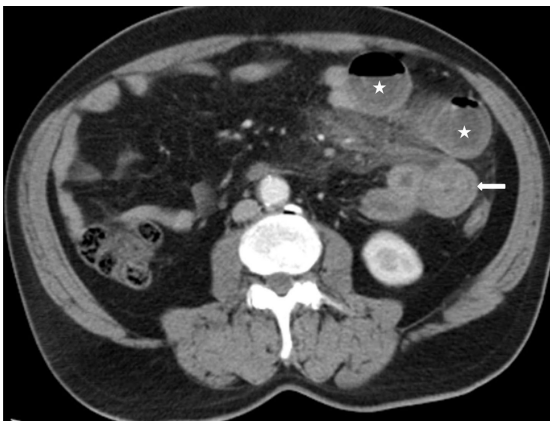
In this case, the patient admitted to the emergency department with acute onset of abdominal pain, was diagnosed as jejunal intramural hematoma. It was observed that the patient also had an association with partial small intestinal.

### Case presentation

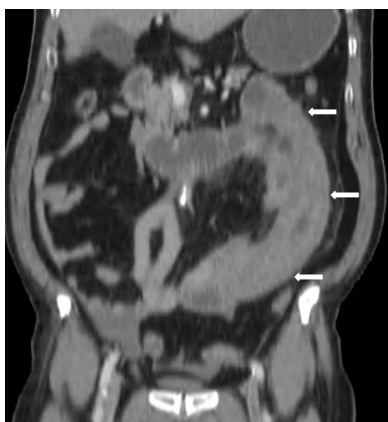A-60 year old male patient was admitted to emergency service complaining of two-days lasting

abdominal pain, constipation, vomiting and hematuria. His medical history consisted of the following: cerebral ischemic infarct (6 years ago), operated right inguinal hernia (2 years ago) and major depression (on going for 2 years).

The patient was observed to have a heart rate of 106 bpm and a blood pressure of 90/50mmHg. The respiratory rate was 20 breaths/min. The patient was alert and oriented to person, place and time. Abdomen was sensitive and distended on palpation; intestine sounds were reduced, sensitivity was present on both lower quadrants, no stool was present at rectal touch. Air-fluid levels were determined with plain abdominal X-ray; a nasogastric tube was immediately placed. Intravenous contrast-enhanced computed tomography (CT) scan was taken due to increasing complaints of the patient. Fluid-air levels in the proximal jejunal segment and diffuse wall thickening in the distal jejunal segment with 3 cm thickness was observed on CT. (Figures 1 and 2).



**Figure 1:** Axial CT scan demonstrated the wall thickness of the jejunal segment (arrow) and air-fluid levels in the dilated proximal jejunal segment.



**Figure 2:** Coronal reformatted CT image showed the diffuse wall thickening of the jejunal segment due to hemorrhage.

The INR was 11,3 and the hemoglobin level was 11,5 g/dl. It was noticed that the patient was using Warfarin in 5mg dosages for the past month; however the patient did not know when the last time was and in what dosage he took the medication. Volume replacement was administered with crystalloid fluid infusion and intravenous Vitamin K was performed to the patient. While monitoring in our emergency department the patient was becoming more symptomatic. Blood pressure was 80/40 mmHg and control hemoglobin was 9,5 g/dl. Prothrombin complex concentrate (PCC) (Factor II/VII/IX) 250ie 10 ml 10 vials was administered in the emergency department. Control INR resulted as 1.2 about one hour later and control hemoglobin was not decreased. The patient with normal hemodynamic parameters was hospitalized in general surgery service for follow-up and treatment purposes. The patient's abdomen was relieved in his first day of hospitalization and was able to defecate. He was discharged with the suggestion of polyclinic check-up.

## Discussion

Oral anticoagulant was widely used in many indications such as deep vein thrombosis, persistent atrial fibrillation, etc. The most serious complication associated with the use of warfarin is bleeding due to excess anticoagulation, which occurs in about 7.6% of the patients<sup>(7)</sup>. Bleeding presenting as a partial or a complete bowel obstruction that is secondary to an intramural hematoma is a relatively unusual condition. Although it is generally treated conservatively by nasogastric decompression and total parenteral nutrition (TPN), surgical intervention is required in patients with active bleeding, acute abdominal pain, or intestinal obstruction. Intestinal hematoma should be suspected as the cause of abdominal pain in patients with a history of warfarin use related to prolonged INR value. This symptom usually presented in all patients with varying degree from acute abdominal emergency to cramping pain because of partial bowel obstruction<sup>(3,8)</sup>. On the patient presented with an abdominal pain and accompanied with increase INR value following using of anticoagulant background, it should definitely be stimulant and researched.

Early diagnosis is very important since it responds to the treatment without requiring operation on most patients. Conservative therapy with reversal of anticoagulant therapy is usually sufficient for hemodynamically stable patients.

The duration of anticoagulant cessation should be determined for each individual patient based on their clinical condition and be minimized as much as possible.

When the patient first arrived, his clinical findings were stable; therefore, the patient was approached in the conventional treatment. However, when the patient lost his clinical stability and experienced a fast decline in his hemogram level, it was appropriate to apply the PCC because of its low-risk factor; thus a rapid reversal of the coagulation was obtained.

Rapid reversal of coagulopathy in unstable geriatric patients on warfarin is vital to limit the extent of hemorrhage. PCC administration with concomitant vitamin K is recommended to facilitate the emergency reversal of oral anticoagulation. PCC allows a much more rapid reversal than standard treatment with only vitamin K and fresh frozen plasma. A growing number of studies have shown that PCC facilitate the rapid and predictable reversal of vitamin K antagonist therapy in these patients with acute bleeding or requiring emergency surgery<sup>(6)</sup>. PCCs are an efficacious and well-tolerated in cases of vitamin K-dependent anticoagulation reversal.

In this case, although there is no risk factor, INR was reduced quickly by using PCC and this raised the possibility of patient's treatment without complication.

### Conclusion

Oral anticoagulants are a mainstay in current clinical practice. Like most medications, these drugs come with some potential adverse events, including an increased risk of bleeding. A spontaneous intramural intestinal hematoma is a rare complication of the anticoagulant therapy. PCC may be considered for rapid reversal of coagulopathy in a unstable patient in the emergency service.

### References

- 1) Souirti Z, Messouak O, Belahsen F. *Cerebral venous thrombosis: a Moroccan retrospective study of 30 cases*. PanAfr Med J. 2014; 17: 281.
- 2) Uysal E, Çevik E, Solak S, Acar YA, Yalimol M. *A life-threatening complication of warfarin therapy in ED: diffuse alveolar hemorrhage*. Am J Emerg Med. 2014; 32: 690.e3-4.
- 3) Jimenez J. *Abdominal pain in a patient using warfarin*. Postgrad Med J. 1999; 75: 747-48.
- 4) Veldt BJ, Haringsma J, Florijn KW, Kuipers EJ. *Coumarin-induced intramuralhematoma of the duodenum: case report and review of the literature*. Scand J Gastroenterol. 2011; 46: 376-79.
- 5) Sorbello MP, Utiyama EM, Parreira JG, Birolini D, Rasslan S. *Spontaneous intramural small bowel hematoma induced by anticoagulant therapy: review and case report*. Clinics (Sao. Paulo); 2007; 62: 785-790.
- 6) Borsaru AD, Nandurkar D. *Intramural duodenal haematoma presenting as a complication after endoscopic biopsy*. Australas Radiol 2007; 51: 378-80.
- 7) Matthews SS, Ringeisen AL, Wedro B. *Intentional overdose of warfarin in an adult: anticoagulant reversal in the ED*. Am J Emerg Med. 2014; 32: 1150.e1-2.
- 8) Lancelot L, Rakesh K, Kishan Prasad HL, Balakrishna S. *Colon Obstruction due to an Anticoagulant Induced Intramural Haematoma; A Rare Case Report*. Journal of Clinical and Diagnostic Research. 2013; 7: 739-41.

### Corresponding author

BEDIA GULEN, MD  
Attending Physician of Emergency Medicine  
Bezmialem University School of Medicine,  
Department of Emergency Medicine,  
Istanbul  
(Turkey)