

# A missed Behçet's case presenting with spontaneous epidural hematoma

Levent Karataş<sup>1</sup>, Gönen Mengi<sup>2</sup>, Özden Özyemişçi-Taşkıran<sup>3</sup>

## Abstract

Spinal vascular events related to Behçet's disease are relatively uncommon. Deep vein thrombosis is the most frequent vascular involvement. Anticoagulant therapy is a debated issue in Behçet's disease. In this case report, we present a patient with a delayed diagnosis of Behçet's disease after development of cervical epidural hematoma following anticoagulant therapy due to deep venous thrombosis. Anticoagulant therapy without immunosuppressive therapy leading to uncontrolled systemic inflammation may be the cause of spinal epidural hematoma. On the other hand, epidural vascular involvement as a vasculitic manifestation of Behçet's disease in conjunction with anticoagulant therapy may have predisposed to spontaneous bleeding via increased fragility or microaneurysms in epidural arteries. In this case report, the importance of a multidisciplinary approach to Behçet's disease is emphasized.

**Keywords:** Behçet's disease, spinal epidural hematoma, anticoagulants

## Introduction

Behçet's disease is a multisystemic disease which can present with various organ system involvements such as mucocutaneous, ophthalmic, musculoskeletal, vascular, neurogenic, gastrointestinal manifestations. The disease may evolve by the cumulation of symptoms within months/years. Holistic approach to the Behçet's patient and immunosuppressive treatment are essential in the management (1).

Vascular manifestations have been reported in 7.7-38% of Behçet's patients. Deep vein thrombosis is the most frequent vascular involvement (2). Spinal vascular events related to Behçet's disease are relatively uncommon (3).

Spontaneous spinal epidural hematoma (SEH) is a rare condition with an estimated incidence of 0.1/100,000 (4). Coagulopathy, vascular malformation, and malignancy are non-traumatic causes of SEH (5). On the other hand, the use of unfractionated heparin, warfarin, aspirin, and tissue plasminogen activator may predispose to spontaneous SEH (6). Anticoagulant therapy in Behçet's disease is a debated issue. There is no controlled study regarding the necessity of anticoagulant therapy in vascular involvement of Behçet's disease (1). Moreover, inattentive anticoagulation therapy increases the risk of hemorrhage especially in the presence of an aneurysm or other vascular malformations.

To our knowledge there has been no report of SEH in a Behçet's case treated with/without anticoagulant therapy. In this case report, we present a patient with a delayed diagnosis of Behçet's disease after development of cervical SEH following anticoagulant therapy due to deep venous thrombosis.

## Case Presentation

A 42-year-old man was admitted to our outpatient clinic due to weakness in extremities. Three months ago, numbness in his extremities, progressive muscle weakness causing impairment of gait and urinary retention developed within a 24-hour period following a sudden and severe neck pain. No history of antecedent trauma, iterative coughing or spinal invasive procedure was reported. He had been on warfarin prescribed by a cardiovascular surgeon for three months because of bilateral deep venous thrombosis with pulmonary embolism. Prothrombin time (PT) expressed as international normalized ratio (INR) was not monitored regularly during this period. MRI revealed a cervical epidural hematoma spanning posterolaterally on the right side between C4 and C6 vertebral levels (Figure 1, 2). INR value was found to be 3.81 and an urgent surgical decompression within 36 hours after the first symptom was carried out.

At the time of admission to our outpatient clinic following surgery, muscle strength and ambulation had improved. However he complained about diminished effort level, difficulty in walking and urinary



1 Department of Physical Medicine and Rehabilitation, Gazi University Faculty of Medicine, Ankara, Turkey

2 Department of Rheumatology, Muğla Sıtkı Koçman University Faculty of Medicine, Muğla, Turkey

3 Department of Physical Medicine and Rehabilitation, Koç University Faculty of Medicine, İstanbul, Turkey

Address for Correspondence:  
Gönen Mengi, Sıtkı Koçman Üniversitesi  
Tıp Fakültesi, Romatoloji Anabilim Dalı,  
Muğla, Türkiye

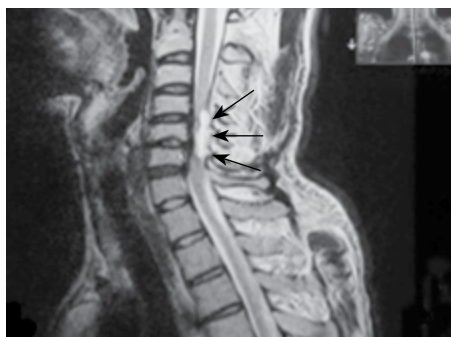E-mail: [gonenmengi@gmail.com](mailto:gonenmengi@gmail.com)

Submitted: 08.02.2015

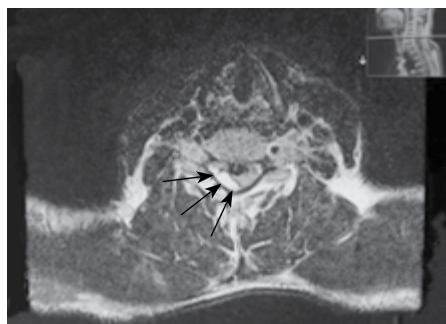
Accepted: 25.02.2015

Available Online Date: 24.06.2015

Copyright 2015 © Medical Research and Education Association



**Figure 1.** Magnetic resonance imaging, T2 sagittal image. Arrows outline the hematoma spanning between C4-C6 levels



**Figure 2.** Magnetic resonance imaging, T2 axial image at C4-C5 level. Arrows indicate the hematoma displacing the cervical cord to the left

problems. A further detailed history revealed that he had frequent oral aphthous ulcers and posterior uveitis sequela in the left eye. History of genital ulcers, erythema nodosum or other skin lesions was absent. Physical examination revealed hypoesthesia below C6 bilaterally. Manual muscle testing showed weakness in C8 and below myotomes bilaterally, with a score of 4/5. Deep tendon reflexes of upper and lower extremities were hyperactive. Plantar reflexes and Hoffmann's signs were positive bilaterally. Ambulation on level surfaces was safe and independent, however physical assistance was required on non-level surfaces. Anal sphincter tonus was normal and bulbocavernosus reflex was present. Neurological examination indicated a C8 level incomplete tetraplegia.

Behçet's disease was diagnosed after occurrence of an incomplete spinal cord injury with the above history and physical findings. Azathioprine 2 mg/kg/day and acetylsalicylic acid 150 mg/day were commenced. Also, a rehabilitation program consisted of muscle strengthening, motor coordination and aerobic exercises was prescribed. A written informed consent was taken from the patient for this case presentation.

## Discussion

Spontaneous SEH is rare (especially in Behçet's disease) and if it is located at high cervical levels, it can be lethal (5). Etiology and origin of spontaneous SEH mostly can not be detected. Factors such as sudden increases in intraabdominal and intrathoracic pressure may be responsible for the rupture of epidural venous plexus resulting in epidural hematoma (7). However some authors suggest that pressure in cervical epidural veins is lower than that of cerebrospinal fluid, so epidural venous hemorrhages could not compress the spinal cord like arterial ones. A short period between pain onset and neurological impairments like in our case suggests an arterial bleeding. Cervical and

upper extremity stretching movements may result in rupture of epidural small arteries, especially at lower cervical levels (5). In our case hematoma was detected at mid cervical level, consistent with the literature, but no history of upper extremity, cervical stretching movement or heavy lifting was noted.

Until now, the role of anticoagulant therapy has remained controversial in the management of deep venous thrombosis associated with Behçet's disease. While some physicians use anticoagulant therapy, others do not recommend it since the underlying mechanism is endovascular inflammation due to vasculitis (8). Immunosuppressive therapy which adequately controls systemic inflammation seems to be the mainstay in the management of the vascular complications related with Behçet's disease (1). Also anticoagulant therapy is commonly the cause underlying the spontaneous SEH especially in elderly population (9). In our case at the time of epidural hematoma INR value was 3.81 which is close to the upper end of therapeutic range; but SEH may happen in individuals who take oral anticoagulants even though INR levels are not very high (5).

Vasculitic manifestations of Behçet's disease may affect all size of arteries and veins. Vasculitis, arterial aneurysm and arteriovenous malformations are characterized by vessel fragility and predispose to spontaneous bleeding which may lead to neurologic deficits (10). Considering deep venous thrombosis, uveitis and oral aphthous history, our patient may have been suffering from longstanding inflammation of undiagnosed Behçet's disease. Consequently epidural vascular involvement in conjunction with anticoagulant therapy may have predisposed to spontaneous bleeding via increased fragility or microaneurysms in epidural arteries. Since angiographic evaluation was not available before surgical decompression, we can not prove this hypothesis.

Multidisciplinary approach and collaboration are important in the management of multisystemic diseases like Behçet's disease promoting early recognition and treatment. Individual treatments provided by the ophthalmologists, cardiovascular surgeons or dermatologists without holistic view would lead to a delay in diagnosis. Delayed diagnosis and treatments may conclude with unexpected permanent sequelae and even death.

**Ethics Committee Approval:** N/A.

**Informed Consent:** Written informed consent was obtained from the patient.

**Peer-review:** Externally peer-reviewed.

**Author Contributions:** Concept - L.K., G.M., Ö.Ö.T.; Design - L.K., G.M., Ö.Ö.T.; Supervision - G.M., Ö.Ö.T.; Materials - L.M.; Data Collection and/or Processing - L.M., G.M.; Analysis and/or Interpretation - L.K., G.M., Ö.Ö.T.; Literature Review - L.K., G.M., Ö.Ö.T.; Writer - L.K., G.M.; Critical Review - G.M., Ö.Ö.T.

**Conflict of Interest:** No conflict of interest was declared by the authors.

**Financial Disclosure:** The author declared that this study has received no financial support.

## References

1. Saleh Z, Arayssi T. Update on the therapy of Behçet disease. *Ther Adv Chronic Dis* 2014; 5: 112-34. [CrossRef]
2. Owlia MB, Mehrpoor G. Behçet's disease: New concepts in cardiovascular involvements and future direction for treatment. *ISRN Pharmacol* 2012; 2012: 760484.
3. Duman I, Guzelkucuk U, Tezel K, Aydemir K, Yilmaz B. Behçet's disease presenting with sudden-onset paraplegia due to anterior spinal artery involvement: 1-year follow-up of rehabilitation in conjunction with medication. *Rheumatol Int* 2013; 33: 1605-8. [CrossRef]
4. Liu Z, Jiao Q, Xu J, Wang X, Li S, You C. Spontaneous spinal epidural hematoma: analysis of 23 cases. *Surg Neurol* 2008; 69: 253-60. [CrossRef]
5. Beatty RM, Winston KR. Spontaneous cervical epidural hematoma. A consideration of etiology. *J Neurosurg* 1984; 61: 143-8. [CrossRef]
6. Heppner PA, Monteith SJ, Law AJ. Spontaneous spinal hematomas and low-molecular-weight heparin. Report of four cases and review of the literature. *J Neurosurg Spine* 2004; 1: 232-6. [CrossRef]
7. Pear BL. Spinal epidural hematoma: Am J Roentgenol. *Radiat Ther Nucl Med* 1972; 115: 155-64. [CrossRef]
8. İlhan G, Bozok S, Uguz E, Karamustafa H, Karakisi SO, Sener E. Management of extensive venous thrombosis following cardiac surgery in a patient with Behçet's disease. *Vasa* 2012; 41: 301-5. [CrossRef]
9. Groen RJ, Ponsse H. The spontaneous spinal epidural hematoma. A study of the etiology. *J Neurol Sci* 1990; 98: 121-38. [CrossRef]
10. Romero-Vargas S, Ruiz-Sandoval JL, Barges-Coll J, Espejo I, Sotomayor-Gonzalez A, Mendez-Rosito D, Ariada-Mendicoa N. Pathological demonstration of cervical spinal cord inflammatory vasculitis in a patient with spontaneous spinal epidural haematoma associated with systemic lupus erythematosus. *Neuropathol Appl Neurobiol* 2010; 36: 568-70. [CrossRef]