

Which Tyrosine Kinase Inhibitor Must We Apply Before? A Case Report of Crizotinib-resistant Patient with Concomitant EGFR and EML4-ALK Gene Mutations

S Cokmert¹, A Veral², N Akyurek³, SD Kececi⁴, O Sivrikoz⁴, E Yilmaz⁵, O Tanriverdi⁶, U Coskun⁷

ABSTRACT

The concomitant epidermal growth factor receptor (EGFR) mutation and anaplastic lymphoma kinase (ALK) translocations in lung adenocancers are very rare scenarios. Until now, 42 cases described in the literature have all been treated by different drugs. There is no overall consensus regarding the treatment for this adenocarcinoma subgroup. We report here a case of lung adenocarcinoma with concomitant EGFR mutation in exon 21 (L858R) and ALK rearrangement in primary tumour, EGFR mutation in exon 21 (L858R) and no ALK rearrangement in its synchronous metastasis. We treated this patient with crizotinib as the second-line therapy (after the first line docetaxel–cisplatin chemotherapy), but no response was obtained. The therapeutic choice for the lung adenocancer patients with concomitant EGFR mutation and ALK rearrangement is unclear. Examination of c-ros oncogene 1 mutation can be used as an indicator in the prediction of the crizotinib treatment success. The ALK mutation may not responsible for the resistance to EGFR-tyrosine kinase inhibitors (TKI), and EGFR-TKI can be initiated to EGFR and ALK dual mutant patients as the first treatment.

Keywords: Adenocancer, anaplastic lymphoma kinase, crizotinib, lung epidermal growth factor receptor mutation

INTRODUCTION

Non-small cell lung cancer (NSCLC) comprises 85% of all the lung cancers and most of them show adenocarcinoma histology (1). Pre-treatment detection of epithelial growth factor receptor (EGFR) and the anaplastic lymphoma kinase (ALK) mutations is of importance regarding obtaining a significantly better clinical response with tyrosine kinase inhibitors (TKI), compared to conventional chemotherapy drugs (2). Epithelial growth factor receptor and ALK mutations are seen simultaneously very rarely; however, they are reported in considerable numbers in case series and studies, such as 11.8–15.8% (3), and there is no full consensus regarding the treatment for adenocarcinoma subgroup. In this paper, we present a female patient

with lung adenocarcinoma with EGFR and ALK dual mutations, and no response to crizotinib treatment.

CASE REPORT

A female patient, aged 64, was admitted to the neurosurgery department in May 2014 with lower back pain complaints, extending to legs, which existed for 5–6 months. In the patient's past medical history, it was determined that the patient worked in the tobacco rolling department at a tobacco factory for 20 years, had no additional co-morbid diseases and has never smoked. In her family history, her father died of lung cancer and has never smoked.

In the examination of the patient, right sciatica, 5/4 paresis in the right big toe dorsiflexion, ++/+ decrease

From: ¹Department of Medical Oncology, Medicana International Ankara Hospital, Ankara, Turkey, ²Department of Pathology, School of Medicine, Ege University, Izmir, Turkey, ³Department of Pathology, School of Medicine, Gazi University, Ankara, Turkey, ⁴Department of Pathology, School of Medicine, Sifa University, Izmir, Turkey, ⁵Department of Radiology, School of Medicine, Sifa University, Izmir, Turkey, ⁶Department of Medical Oncology,

School of Medicine, Mugla Sıtkı Koçman University, Mugla, Turkey and ⁷Department of Medical Oncology, School of Medicine, Gazi University, Ankara, Turkey.

Correspondence: Dr S Cokmert, Department of Medical Oncology, Medicana International Ankara Hospital, Cankaya, Ankara, Turkey. Email: sunacok@gmail.com

in the deep tendon reflexes were determined. In the thoracic magnetic resonance imaging (MRI) examination, there was a $55 \times 47 \times 50$ mm lesion at T9-10-11 levels in the expansile structure, extending to spinal canal in posterior and contacting with spinal cord from left anterior, and a $23 \times 16 \times 30$ mm mass at the right upper lung lobe apicoposterior, located close to pleura with irregular contours at T2-3-4 levels.

Due to spinal compression signs, radical mass resection and stabilization operations were applied to the patient. Pathological examination of the resected mass was reported as malign epithelial tumour metastasis, pancytokeratin (+), vimentin focal (+), TTF-1 (+) and P53 (+), and lung cancer was considered as the primary tumour. Pathological examination of trucut biopsy taken from $23 \times 16 \times 30$ mm mass at the right upper lung lobe apicoposterior, located close to pleura, was detected as NSCLC related to adenocarcinoma, and tumour material was taken to examination for EGFR and ALK tests.

Awaiting the results of these tests, cisplatin–docetaxel treatment was initiated in the patient with adenocarcinoma diagnosis. Patient's response to treatment was detected as 'progression', following the two cycles of application. In the genetic analysis of the mass located in the lungs, codon 858 mutation was detected at exon 21 with EGFR pyrosequencing method (Fig. 1). Anaplastic lymphoma kinase was determined with the fluorescent *in situ* hybridization (FISH) method, break apart signals were observed in 15% of the cells and ALK re-arrangement was accepted as positive (Fig. 2A). c-ros oncogene

1 (ROS1) could not be conducted as the tumour was not an adequate amount for deoxyribonucleic acid testing.

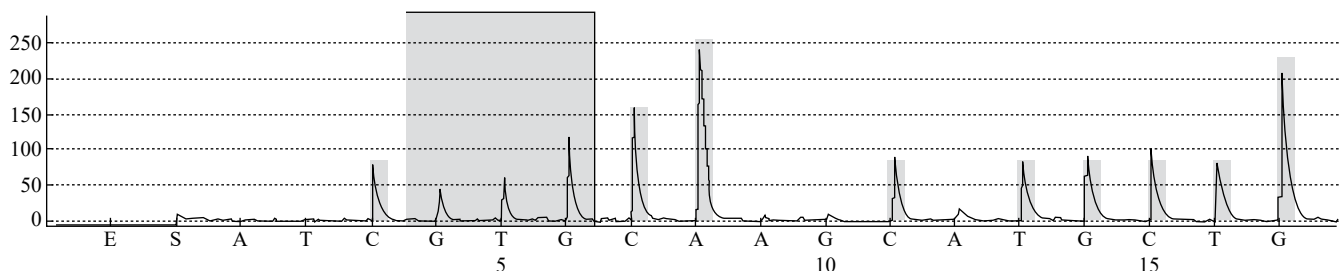
With these findings, the crizotinib was initiated. In the response evaluation following the three-month treatment which was highly tolerable with clinical improvements, it was determined that the mass in the right lung showed progress; however, no recurrence was detected on material from T10 localized, soft-tissue metastasis. In the brain, MRI was carried out for the patient's headache complaints and multiple parenchymal metastases were detected. Due to the severe deterioration of the patient's general condition and performance and her becoming bedridden due to neurological findings during and following the palliative radiation therapy treatment, no treatment could be applied except support treatments and the patient was lost due to aspiration pneumonia.

Regarding the reason for crizotinib resistance, in the retrospective, genetic examination carried out on material from T10 localized, soft-tissue metastasis, codon 858 mutation was detected in exon 21 with real-time polymerase chain reaction (Cobas® 4800 System) method, and no ALK and ROS1 rearrangements were detected with FISH method (Fig. 2B and 2C).

DISCUSSION

In NSCLC, especially the results obtained as a result of genetic and molecular studies in the adenocarcinoma subgroup, there was the necessity for personalized treatment, depending on the presence of driver mutations detected in tumours. The most common driver

Assay: EGFR Codon 858-861
Sample ID: 449-2014 (30274-2014)



Result	Mutation (Codon 858)
Frequency	21,0 % units (LOD: 2,6% units)
Nucleotide Substitution	CTG>CGG
Amino Acid Substitution	L858R
Quality	Passed

Fig. 1: Epidermal growth factor receptor mutation in exon 21 (L858R) in primary lung adenocancer before the crizotinib treatment.




Fig. 2: Fluorescent *in situ* hybridization (FISH) reveals: (A) The results of a break-apart (isolated red signals) FISH assay for ALK rearrangements in primary lung adenocancer. (B) Normal signals, no rearrangement in metastatic lesion of the primary lung adenocancer. Note that some of the signals are fused and produce a yellow signal, while others have green and red signals in close proximity. (C) Normal signals, no rearrangement in metastatic lesion of the primary lung adenocancer. Note that the signals are fused.

mutations seen in NSCLC are epidermal growth factor receptor (EGFR), serine/threonine-protein kinase B-Raf (BRAF), Kirsten Rat Sarcoma Virus (KRAS), mesenchymal epithelium (MET), human epidermal growth factor receptor 2 (HER2), ALK and ROS1 (4, 5), and TKI drugs are used in the treatment in EGFR and ALK mutations.

EGFR mutations with racial differences are seen in 10–35% of all patients (6). In the presence of EGFR mutation, the percentage of response to treatment with EGFR-TKI is known to be 70%. Epithelial growth factor receptor mutation is mostly seen in nonsmoking female individuals with adenocarcinoma histology. The most common EGFR mutations are exon 19 deletion and exon 21 L858R mutation. Epithelial growth factor receptor exon 20 insertions or T790M mutation indicate the patients that show resistance to TKI treatment (7). Echinoderm microtubule-associated protein-like 4-anaplastic lymphoma kinase (EML4-ALK) translocation found in 2007 is detected in 5% of NSCLCs (8).

Patients with such mutations are generally young, with few or no smoking habits and show no EGFR and KRAS mutations. Also, in the presence of ALK mutation, resistance was reported to EGFR-specific TKI

treatment (9). Crizotinib is the first FDA-approved ALK-TKI and the response rate to crizotinib treatment in NSCLC patients in the presence of ALK mutation was detected as 50–61% (10). c-Ros oncogene 1 is an oncogene that encodes a tyrosine kinase receptor and its ROS1 rearrangement in NSCLC was found in 2007. c-Ros oncogene 1 was reported positive in 0.7–1.7% of all the patients. Anaplastic lymphoma kinase-tyrosine kinase inhibitors crizotinib, show high response ratios, such as 72–80% in ROS1 rearranged NSCLC patients (11). c-Ros oncogene 1 can be evaluated as an indicator of response to crizotinib treatment.

One case presented as a case study in recent years is the simultaneous occurrence of EGFR mutation and ALK translocation. Approximately 42 cases were reported in the literature (12–29), and no common property could be determined regarding ALK rearrangements (variant 1–11), while, in terms of EGFR, it is seen that the majority of the cases has EGFR exon 19 mutation (the second most common is the exon 21 mutation). In our case, EGFR exon 21 mutation was detected together with ALK mutation in primary lung mass.

Only 24 of the 42 cases reported in the literature were the EGFR and ALK dual mutation cases with no systemic treatment, in other words, in naive tumour. The remaining 18 cases were either recurrence or EGFR and ALK dual mutations in samples taken from lymph node metastasis developed following chemotherapy or tyrosine kinase treatment. Tiseo *et al*, in the material obtained from surgical resection following the chemotherapy application, reported a case with mutant EGFR in primary mass and lymph node metastasis, negative in primary lung mass and positive in lymph node metastasis (13). In our case, ALK was positive in the primary mass.

While the effect of chemotherapy applied on the detection of ALK rearrangement in lymph node metastasis is unknown, the effect of mutations in tumour cells resistant to chemotherapy is possible. In some cases (14, 15), it was reported that ALK was not mutant in the primary mass, whereas it became mutant in samples taken as a result of progression under the applied treatments, or it was mutant in the primary mass and no mutations were detected after crizotinib treatment. Additionally, Bai *et al* showed that chemotherapy can affect the EGFR mutation status in the tissue and blood (16). Similarly, in the case reported by Sun *et al*, EGFR mutation before the mutation was positive in the pre-treatment period, while EGFR was wild type in recurrence material developed after erlotinib treatment and ALK rearrangement was positive (17). On the contrary, in the case reported

by Baldi *et al*, in both naive tumour and the re-biopsy material taken from the recurrent mass following chemotherapy and erlotinib treatments, EGFR and ALK was detected mutant (18). As is the case with our patient, this is the first report in which ALK is mutant in the primary mass and ‘rearrangement negative’, while the ALK status in both the primary lung mass and its metastasis and EGFR is mutant in both materials before the application of any systemic treatment. Epithelial growth factor receptor/anaplastic lymphoma kinase results in our case are of importance in terms of showing the status before the application of any systemic treatment.

Due to having no response to crizotinib treatment in our case, ALK was detected negative in the (retrospective) examination we conducted in the metastatic material of the tumour. This can be evaluated as the dominant mutation is not ALK in the tumour, and EGFR is the dominant tumour as it is determined to be mutant in both the primary tumor and metastase. As reported in the study by Sasaki *et al* (19), EGFR signalling and EGFR mutation activation can be a mechanism responsible for crizotinib resistance. Due to the multiple brain metastasis and the progression in the primary lung mass in our patient following a three-month crizotinib treatment, re-biopsy could not be performed as the general condition of the patient was not suitable, thus genetic studies related to crizotinib resistance could not be conducted.

Additionally, we evaluate the inability to perform ROS1 in primary mass due to material insufficiency as a major shortcoming and we would like to emphasize the importance of competency of the samples taken from the samples for diagnosis for the conduction of these examinations. Based on the necessity of evaluations of the patient for other mutations (including KRAS, BRAF and HER2) as well as ROS1 for decision-making in clinical practice for the further stages of treatment, appropriate standardization of diagnostic materials that will allow performing these tests is considered a critical point. Regarding the treatment that will be applied on the subjects with EGFR and ALK dual mutants; there is no clear conclusion available according to the reported cases. Won *et al*, in their study, reported that, in 14 dual mutant NSCLC patients, EGFR-TKI was ineffective, while ALK inhibitor was effective (20). There were also studies reporting cases with the objective responses to EGFR-TKI treatment (21–27). Three-year-long stability was maintained with erlotinib in the case reported by Baldi *et al* (28). In the case reported by Tanaka *et al*, EGFR was detected in the re-biopsy material taken after chemotherapy, erlotinib was initiated and positive

ALK was determined in the second re-biopsy material taken from the patient who showed progression after one month’s use (29).

In both cases, reported by Baldi *et al* and Tanaka *et al*, EGFR exon 21 (L858R) mutation was detected, and the case reported by Baldi *et al* showed progression in a long-term response with erlotinib, while progression was determined with erlotinib in the first month of the treatment in the case reported by Tanaka *et al*, and it is seen that different treatment responses were obtained from both cases in which ALK was mutant and EGFR had the mutation with the same localization. Although it was shown in *in vitro* conditions (30), taking ALK mutation as exclusively responsible for erlotinib resistance would not be entirely accurate. In a study supporting our views in the literature, in a patient who received erlotinib treatment, although EGFR was not detected, a stable disease response was received for 15 months and ALK was determined mutant in the pre-erlotinib tumour material in the retrospective tumour material examination (27). Also, in the case reported by Baldi *et al* in which a stable response was received for three years, ALK was detected mutant before and after erlotinib (28).

This difference detected regarding ALK in the primary tumour mass and its soft-tissue metastasis, as is in our case, actually reveals the difficulty of lung cancer treatment and the cause of failures in the treatment. This situation we detected can reflect the status which was described as tumour heterogeneity and therefore we abstain from the opinion by Baldi *et al* regarding the simultaneous presence of EGFR and ALK in the same tumour cell. As we detected in our case (EGFR exon 21 mutation and ALK rearrangement in the primary tumour, EGFR exon 21 mutation in metastasis material, however, no ALK rearrangement) there are different tumour clones with different genetic properties in the tumour.

The role of mutations that became dominant or newly added under the treatment which actually developed due to tumour heterogeneity should be examined as the underlying factor beneath the non-response to treatment which we interpret as EGFR-TKI or ALK-TKI resistance. Examination of ROS1 mutation must be used as an indicator in the choice of the crizotinib treatment. As is the case in many patients, treatment determined according to the genetic properties of the tumour is not fully effective due to the differences in the genetic properties of tumour cells in metastasis regions and possibly in the circulation.

Due to both the high cost of the tests that determine the mutation and the social, ethical and financial

challenges in sampling in primary tumour and metastasis taken from the patient, determination of the treatment in lung cancer is a great challenge. At this point, determination of genetic properties in circulating tumour cells and simultaneous treatment for all present mutations can be important. Our purpose in presenting this case is to bring a new perspective to our clinical practices because depending on the possibility of different EGFR and ALK states in the primary mass and its metastasis in our presented case, we believe that if we conducted the EGFR/ALK examination before the initiation of crizotinib treatment, our choice of treatment would be EGFR-TKI and we would have obtained long-term remission responses similar to those in the literature.

Considering the long-term treatment responses in dual-mutant patients with EGFR-TKI treatments, the hypothesis of 'resistance to EGFR-TKI in the presence of positive ALK' (30, 31) in patients with simultaneous positive EGFR and ALK, at least, is seemingly not valid for all patients. In light of studies showing that ALK mutation is not responsible for the resistance to EGFR-TKI, in an evaluation with the cases in the literature, we believe that EGFR-TKI can be initiated to EGFR (except exon 20 insertions or T790M mutation) and ALK dual-mutant patients as the first treatment. Also, we believe that combined use of EGFR-TKI and ALK-TKI would at least increase the chance of success in patients with dual mutant. Considering the difficulty of re-biopsies that will be applied to the patients, we assume that the determination of dominant mutation according to the examination of circulating tumour cells and the determination of the treatment priorities accordingly can be a strategy. We believe that a whole genetic analysis of dual-mutant patients with long-term responses to EGFR-TKI, with collaborative studies, can improve our knowledge on this subject. There is a need for further investigation in this regard.

ACKNOWLEDGEMENTS

The authors would like to thank the patient and her daughters who shared all their efforts with them.

AUTHORS' NOTE

Written informed consent was obtained from the patient for publication. The authors declare that they have no competing interests.

REFERENCES

1. Zugazagoitia J, Enguita AB, Nuñez JA, Iglesias L, Ponce S. The new IASLC/ATS/ERS lung adenocarcinoma classification from a clinical

perspective: current concepts and future prospects. *J Thorac Dis* 2014; **6**: 526–36.

2. Bronte G, Rizzo S, La Paglia L, Adamo V, Siragusa S, Ficorella C et al. Driver mutations and differential sensitivity to targeted therapies: a new approach to the treatment of lung adenocarcinoma. *Cancer Treat Rev* 2010; **36**: 21–9.
3. Rosell R, Sureda B, Costa C, Molina MA, Gimenez-Capitan A, Karachaliou N et al. Concomitant actionable mutations and overall survival (OS) in EGFR-mutant non-small cell lung cancer (NSCLC) patients (p) included in the EURTAC trial: EGFR L858R, EGFR T790M, TP53 R273H and EML4-ALK (v3). *Ann Oncol* 2012; **23**: abstr 929.
4. Adamson, RT. Biomarkers and molecular profiling in non-small cell lung cancer: an expanding role and its managed care implications. *Am J Managed Care* 2013; **19**: 398–404.
5. Janku F, Stewart DJ, Kurzrock R. Targeted therapy in non-small cell lung cancer—is it becoming a reality? *Nat Rev Clin Oncol* 2010; **7**: 401–14.
6. Li L, Zhang Z, Bie Z, Wang Z, Zhang P, Nie X et al. Epidermal growth factor receptor mutation analysis in cytological specimens and responsiveness to gefitinib in advanced non-small cell lung cancer patients. *Chin J Cancer Res* 2015; **27**: 294–300.
7. Jänne PA, Johnson BE. Effect of epidermal growth factor receptor tyrosine kinase domain mutations on the outcome of patients with non-small cell lung cancer treated with epidermal growth factor receptor tyrosine kinase inhibitors. *Clin Cancer Res* 2006; **12**: 4416–20.
8. Park HS, Lee JK, Kim DW, Kulig K, Kim TM, Lee SH et al. Immunohistochemical screening for anaplastic lymphoma kinase (ALK) rearrangement in advanced non-small cell lung cancer patients. *Lung Cancer* 2012; **77**: 288–92.
9. Shaw AT, Yeap BY, Mino-Kenudson M, Digumarthy SR, Costa DB, Heist RS et al. Clinical features and outcome of patients with non-small-cell lung cancer who harbor EML4-ALK. *J Clin Oncol* 2009; **27**: 4247–53.
10. Kvak EL, Bang YJ, Camidge DR, Shaw AT, Solomon B, Maki RG et al. Anaplastic lymphoma kinase inhibition in non-small-cell lung cancer. *N Engl J Med* 2010; **363**: 1693–703.
11. Rothschild SI. Targeted therapies in non-small cell lung cancer—beyond EGFR and ALK. *Cancers (Basel)* 2015; **7**: 930–49.
12. Santelmo C, Ravaioli A, Barzotti E, Papi M, Poggi B, Drudi F et al. Coexistence of EGFR mutation and ALK translocation in NSCLC: literature review and case report of response to gefitinib. *Lung Cancer* 2013; **81**: 294–6.
13. Tiseo M, Gelsomino F, Boggiani D, Bortesi B, Bartolotti M, Bozzetti C et al. EGFR and EML4-ALK gene mutations in NSCLC: a case report of erlotinib-resistant patient with both concomitant mutations. *Lung Cancer* 2011; **71**: 241–3.
14. Zhang X, Zhang S, Yang X, Yang J, Zhou Q, Yin L et al. RFL4 fusion of EML4 and ALK is associated with development of lung adenocarcinomas lacking EGFR and KRAS mutations and is correlated with ALK expression. *Mol Cancer* 2010; **188**: 1–12.
15. Rossing HH, Grauslund M, Urbanska EM, Melchior LC, Rask CK, Costa JC et al. Concomitant occurrence of EGFR (epidermal growth factor receptor) and KRAS (V-Ki-ras2 Kirsten rat sarcoma viral oncogene homolog) mutations in an ALK (anaplastic lymphoma kinase)-positive lung adenocarcinoma patient with acquired resistance to crizotinib: a case report. *BMC Res Notes* 2013; **489**: 1–8.
16. Bai H, Wang Z, Wang Y, Zhuo M, Zhou Q, Duan J et al. Detection and clinical significance of intratumoral EGFR mutational heterogeneity in Chinese patients with advanced non-small cell lung cancer. *PLoS One* 2013; **8**: e54170.
17. Miyanaga A, Shimizu K, Noro R, Seike M, Kitamura K, Kosaihiro S et al. Activity of EGFR-tyrosine kinase and ALK inhibitors for EML4-ALK-rearranged non-small-cell lung cancer harbored coexisting EGFR mutation. *BMC Cancer* 2013; **13**: 262.
18. Lee JK, Kim TM, Koh Y, Lee SH, Kim DW, Jeon YK et al. Differential sensitivities to tyrosine kinase inhibitors in NSCLC harbouring EGFR mutation and ALK translocation. *Lung Cancer* 2012; **77**: 460–3.

19. Sasaki T, Koivunen J, Ogino A, Yanagita M, Nikiforow S, Zheng W et al. A novel ALK secondary mutation and EGFR signaling cause resistance to ALK kinase inhibitors. *Cancer Res* 2011; **71**: 6051–60.
20. Won JK, Keam B, Koh J, Cho HJ, Jeon YK, Kim TM et al. Concomitant ALK translocation and EGFR mutation in lung cancer: a comparison of direct sequencing and sensitive assays and the impact on responsiveness to tyrosine kinase inhibitor. *Ann Oncol* 2015; **26**: 348–54.
21. Ali G, Chella A, Lupi C, Proietti A, Niccoli C, Boldrini L et al. Response to erlotinib in a patient with lung adenocarcinoma harbouring the EML4-ALK translocation: a case report. *Oncol Lett* 2015; **9**: 1537–40.
22. Kuo YW, Wu SG, Ho CC, Shih JY. Good response to gefitinib in lung adenocarcinoma harboring coexisting EML4-ALK fusion gene and EGFR mutation. *J Thorac Oncol* 2010; **5**: 2039–40.
23. Yang JJ, Zhang XC, Su J, Xu CR, Zhou Q, Tian HX et al. Lung cancers with concomitant EGFR mutations and ALK rearrangements: diverse responses to EGFR-TKI and crizotinib in relation to diverse receptors phosphorylation. *Clin Cancer Res* 2014; **20**: 1383–92.
24. Chiari R, Duranti S, Ludovini V, Bellezza G, Pireddu A, Minotti V et al. Long-term response to gefitinib and crizotinib in lung adenocarcinoma harboring both epidermal growth factor receptor mutation and EML4-ALK fusion gene. *J Clin Oncol* 2014; **32**: e30–2.
25. Popat S, Vieira de Araújo A, Min T, Swansbury J, Dainton M, Wotherspoon A et al. Lung adenocarcinoma with concurrent exon 19 EGFR mutation and ALK rearrangement responding to erlotinib. *J Thorac Oncol* 2011; **6**: 1962–3.
26. Chen X, Zhang J, Hu Q, Li X, Zhou C. A case of lung adenocarcinoma harboring exon 19 EGFR deletion and EML4-ALK fusion gene. *Lung Cancer* 2013; **81**: 308–10.
27. Qiong S, Jian-Yu W, Shun-Chang J. Heterogeneity of epidermal growth factor receptor mutations in lung adenocarcinoma harboring anaplastic lymphoma kinase rearrangements: a case report. *Oncol Lett* 2014; **8**: 2093–95.
28. Baldi L, Mengoli MC, Bisagni A, Banzi MC, Boni C, Rossi G. Concomitant EGFR mutation and ALK rearrangement in lung adenocarcinoma is more frequent than expected: report of a case and review of the literature with demonstration of genes alteration into the same tumor cells. *Lung Cancer* 2014; **86**: 291–5.
29. Tanaka H, Hayashi A, Morimoto T, Taima K, Tanaka Y, Shimada M et al. A case of lung adenocarcinoma harboring EGFR mutation and EML4-ALK fusion gene. *BMC Cancer* 2012; **12**: 558.
30. Koivunen JP, Mermel C, Zejnullahu K, Murphy C, Lifshits E, Holmes AJ et al. EML4-ALK fusion gene and efficacy of an ALK kinase inhibitor in lung cancer. *Clin Cancer Res* 2008; **14**: 4275–83.
31. Shaw AT, Yeap BY, Mino-Kenudson M, Digumarthy SR, Costa DB, Heist RS et al. Clinical features and outcome of patients with non-small-cell lung cancer who harbor EML4-ALK. *J Clin Oncol* 2009; **27**: 4247–53.

© West Indian Medical Journal 2021.

This is an article published in open access under a Creative Commons Attribution International licence (CC BY). For more information, please visit https://creativecommons.org/licenses/by/4.0/deed.en_US.

