

Critical left main coronary artery stenosis in a patient with homozygous familial hypercholesterolemia and aortic valve replacement

Homozigot ailevi hiperkolesterolemi ve aort kapak replasmanlı hastada kritik sol ana koroner darlığı

-  Nuri Köse, M.D.¹
-  Tamer Kırat, M.D.¹
-  Gökhan Ergün, M.D.²
-  İbrahim Altun, M.D.²
-  Fatih Akın, M.D.²

¹Department of Cardiology, Yücelen Hospital, Muğla, Turkey

²Department of Cardiology, Muğla Sıtkı Koçman University, School of Medicine, Muğla, Turkey

A 45-year-old male was admitted to cardiology clinic with a history of exertional angina (Canadian Cardiovascular Society Class III) for 3 months. He had been diagnosed with homozygous familial hypercholesterolemia (HoFH) 10 years ago. In addition,

his mother, father, and 2 brothers also had history of familial hypercholesterolemia. He had undergone mechanical aortic valve replacement due to severe symptomatic aortic stenosis 10 years ago. A coronary angiography before valve replacement reported plaques in the coronary arteries. The patient had xanthomas on the dorsum of both hands and Achilles' tendon, the latter of which had appeared in childhood and resected under local anesthesia 2 years ago. He had been on atorvastatin (80 mg/day), ezetimibe (10 mg/day), and warfarin treatment for 10 years. However, he stated that he had stopped lipid-lowering medications a month ago. In physical examination, blood pressure was 120/80 mmHg, with a pulse of 72 bpm. Bilateral arcus cornealis and palpebral xanthelasma (Figure 1A) and, although partially resected, xanthomas in the Achilles tendon were evident in inspection (Figure 1B). His serum total cholesterol levels was 662 mg/dL, low density lipoprotein (LDL) cholesterol was 604 mg/dL, high-density lipoprotein cholesterol was 30 mg/dL, and triglyceride level was 140 mg/dL. ECG revealed a normal sinus rhythm. In transthoracic echocardiography, normal functioning prosthetic metallic aortic valve (maximum gradient 24 mmHg), mild mitral regurgitation, and mild left ventricular hypertrophy with a normal left ventricular ejection fraction were detected. A 43-mm focal aortic root aneurysmal dilatation and calcification in the ascending aorta were determined in both the thoracic computerized tomography and conventional

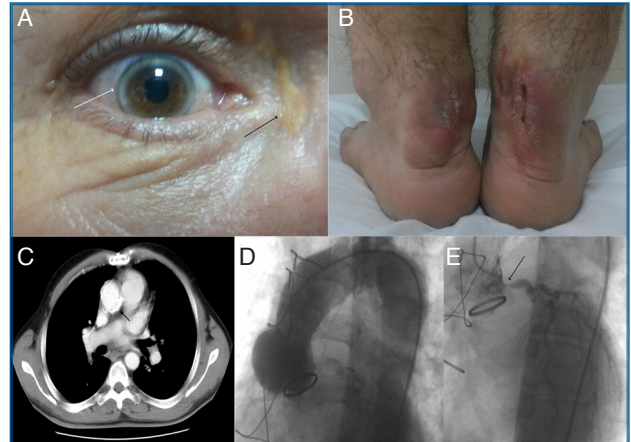


Figure 1. (A) Arcus senilis in the right cornea (white arrow) and xanthelasma in the right palpebra (black arrow); (B) Xanthoma of Achilles tendons after operation; (C) Contrast-enhanced computed tomography images showing diffuse calcium plaques in the ascending aorta (arrow); (D) Focal aneurismatic dilatation of aortic root is seen in the aortography; (E) Left main coronary artery lesion with significant ostial stenosis (arrow).

aortography (Figure 1C and D). Coronary angiography revealed an ostial stenosis of 80% in the left main coronary artery with some plaques in the other coronary arteries (Figure 1E). The patient was referred to surgery. The left internal mammary artery to the left anterior descending artery and a saphenous vein to the obtuse marginal artery bypass grafts were applied. Despite intensive therapy with atorvastatin 80 mg/day and ezetimibe 10 mg/day, his total cholesterol was 549 mg/dL and LDL cholesterol was 461 mg/dL. Because of the very high risk of the development of cardiovascular events, more effective means of LDL reduction (by LDL-apheresis, PCSK9 inhibitor, and/or lomitapide) should be afforded for this HoFH patient, with a close follow-up to prevent the premature death and morbidity in line with the recommendations of current guidelines.

Informed consent was obtained from the patient for the publication of the case image and the accompanying images.



Copyright of Turk Kardiyoloji Dernegi Arsivi is the property of KARE Publishing and its content may not be copied or emailed to multiple sites or posted to a listserv without the copyright holder's express written permission. However, users may print, download, or email articles for individual use.