

The effects of tacrolimus and mycophenolate mofetil on regression of encapsulating peritoneal sclerosis in a rat model

Efectos del tacrolimus y el micofenolato mofetil en la regresión de la esclerosis peritoneal encapsulante en ratas

Bülent Huddam¹, Simge Sasmaz², Nihan Haberal³, Alper Azak⁴, Dilek Gibyeli Genek¹, Gulay Kocak⁵, Volkan Karakus⁶, Alper Alp¹, Murat Duranay⁷

ABSTRACT

Objective: Encapsulating peritoneal sclerosis (EPS) is a rare, but potentially fatal complication of peritoneal dialysis. Currently, treatment of peritoneal fibrosis is not fully possible yet. In this study, we aimed to demonstrate the effects of tacrolimus therapy on peritoneal fibrosis and inflammation when administered alone or with mycophenolate mofetil (MMF) in the EPS model induced in rats. **Methods:** Thirty six Wistar albino rats were separated into six equal groups. Group I was the control group. Group II-VI were administered intraperitoneal chlorhexidine (CH) for induced EPS model in rats. Group II, IV, V, VI were administered isotonic liquid, tacrolimus, tacrolimus and concurrently with CH, tacrolimus and MMF together, respectively. Group III was not administered any drug. All peritoneal samples were stained immunohistochemically with matrix metalloproteinase-2 (MMP-2) antibody. Thickness of peritoneal fibrosis, subserosal large collagen fibers, subserosal fibroblast proliferation and subserosal fibrotic matrix deposition were

evaluated. **Results:** Comparing the experimentally induced EPS groups, the best histopathological results and the largest staining with MMP-2 were achieved in Group VI. Furthermore, in all treatment groups (IV, V, VI) more staining with MMP-2 was detected compared to non-treatment groups (I, II, III) but no statistically significant differences were found among all groups. A statistically significant remission was observed in all histopathological parameters, primarily peritoneal thickness in rats that were administered MMF with tacrolimus, compared to rats which were administered tacrolimus only. **Conclusion:** Concurrent use of tacrolimus and MMF in the treatment of EPS may be a promising approach.

KEYWORDS: renal dialysis; peritoneal dialysis; encapsulating peritoneal sclerosis; tacrolimus; mycophenolate mofetil

RESUMEN

Objetivos: La esclerosis peritoneal encapsulante (EPE) es una complicación rara, pero

Correspondencia:
Dr. Alp Alper
ORCID: 0000-0001-5507-4072
alperalp@mu.edu.tr

Financiamiento:
Ninguno.

Conflicto de intereses:
Ninguno

Recibido: 01-06-2021
Aceptación: 09-08-2021

- 1) Mugla Sıtkı Kocman University, School of Medicine, Department of Nephrology, Mugla, Turkey
- 2) Hitit University Erol Olçok Training and Research Hospital, Department of Internal Medicine, Çorum, Turkey
- 3) Baskent University, Faculty of Medicine, Department of Pathology, Ankara, Turkey
- 4) Ministry of Health, Balıkesir State Hospital, Nephrology, Balıkesir, Turkey
- 5) Ministry of Health, Okmeydanı Training and Research Hospital, Nephrology, Istanbul, Turkey
- 6) Alanya Alaaddin Keykubat University, Faculty of Medicine, Department of Hematology, Alanya-Antalya, Turkey
- 7) Ankara Education and Research Hospital, Department of Nephrology, Ankara, Turkey

potencialmente fatal de la diálisis peritoneal. Actualmente, el tratamiento de la fibrosis peritoneal aún no es posible. En este estudio, apuntamos a demostrar los efectos de la terapia con tacrolimus en la fibrosis peritoneal y la inflamación cuando se administran solos o con micofenolato de mofetilo (MMF) en el modelo EPE inducido en ratas. Métodos: Treinta y seis ratas Wistar albinas se separaron en seis grupos iguales. El Grupo I era el grupo de control. En los grupos II-VI se administró clorhexidina intraperitoneal (CH) para el modelo EPE inducido en ratas. En los Grupos II, IV, V, VI se administró respectivamente líquido isotónico, tacrolimus, tacrolimus y CH y finalmente tacrolimus y MMF juntos. El grupo III no recibió ningún medicamento. Todas las muestras peritoneales se tiñeron inmunohistoquímicamente con el anticuerpo Matrix Metaloproteinasa-2 (MMP-2). Se evaluó el grosor de la fibrosis peritoneal, se evaluaron las fibras de colágeno grandes subserosas, la proliferación de fibroblastos subserosa y la deposición de la matriz fibrótica subserosa. **Resultados:** Comparando los grupos de EPE inducidos experimentalmente, los mejores resultados histopatológicos y la tinción con MMP-2 más extensa se lograron en el Grupo VI. Además, en todos los grupos de tratamiento (IV, V, VI) se detectó más tinción con MMP-2 en comparación con los grupos de no tratamiento (I, II, III), pero no se encontraron diferencias estadísticamente significativas entre todos los grupos. Se observó una remisión estadísticamente significativa en todos los parámetros histopatológicos, principalmente el espesor peritoneal en ratas que recibieron MMF con tacrolimus, en comparación con las ratas que recibieron solo tacrolimus. **Conclusión:** El uso concurrente de tacrolimus y MMF en el tratamiento de EPS puede ser una aplicación prometedora.

PALABRAS CLAVE: diálisis renal; diálisis peritoneal; esclerosis peritoneal encapsulante; tacrolimus; micofenolato mofetil

INTRODUCTION

Peritoneal dialysis (PD) is one of the renal replacement therapies available at end-stage renal disease (ESRD) with historically demonstrated efficacy and safety. Changes that develop over time

in the peritoneal membrane lead to inefficiency and eventual termination of peritoneal dialysis.⁽¹⁻²⁾ Peritoneal fibrosis develops as a result of peritoneal mesothelial cell and/or peritoneal fibroblastic hyperplasia and over-accumulation of collagenous matrix due to increased production by these cells.⁽¹⁻²⁾ Matrix metalloproteinases (MMPs) and tissue inhibitors of metalloproteinases (TIMPs) play a role in the initiation and promotion of fibrosis.⁽³⁾ It was shown that MMPs and TIMPs are produced by peritoneal mesothelial cells, fibroblasts and macrophages in the peritoneum. The amount of extracellular matrix in the newly-forming fibrotic structure depends on the ratio of active MMPs to TIMPs.⁽⁴⁻⁵⁾ The pathological changes that develop in the peritoneal membrane may advance into encapsulating peritoneal sclerosis (EPS), which is a serious complication of PD. There is currently no medical therapy available that would help regress fibrosis after the development of peritoneal fibrosis. Therefore, advanced experimental studies are needed to identify treatment options that may be used in patients with EPS, before it advances to the next stage of peritoneal fibrosis, which has fairly undesired consequences.

Immunosuppressive effect of tacrolimus (Tac) is thought to be through the inhibition of calcineurin as well as inhibition of antigen specific T cell activation and release of inflammatory cytokines such as interleukin-4 (IL-4), interleukin-5 (IL-5) and interleukin-2 (IL-2).⁽⁶⁾ It has pro and anti-inflammatory actions and prevention of reperfusion damage in addition to its immunosuppressive function.⁽⁷⁻⁸⁾ Although tacrolimus has been reported to cause nephrotoxicity by stimulating fibrosis in the kidneys in the long term use, there have been studies in which it has shown a paradoxical antifibrotic action in bleomycin-induced lung fibrosis.⁽⁹⁻¹¹⁾ However, there are no studies available regarding the effects of tacrolimus on peritoneal fibrosis.

Mycophenolate mofetil (MMF) inhibits the metabolic pathways for the development of T and B cells and shows immunosuppressive action. Besides, it also demonstrates an antiinflammatory action by blocking lymphocyte and monocyte adhesion in the area of inflammation. It also has an antiproliferative effect on vascular smooth muscle cells. In various recent studies antifibrotic action of MMF was shown.⁽¹²⁻¹³⁾ MMF has been found to

ameliorate peritoneal fibrosis in 2 animal studies.^(12, 14) Similarly, in 3 cases with encapsulated peritoneal sclerosis, the administration of MMF coupled with steroid therapy has been reported to be effective for fibrosis.⁽¹⁵⁾

Tac and MMF are immunosuppressive agents used together in renal transplant patients. The effect, if any, of standalone tacrolimus on peritoneal fibrosis, as well as any additive effects Tac and MMF may have is currently unexplored. In this study, we aimed to evaluate the effects of tacrolimus administered alone or with MMF on peritoneal fibrosis and inflammation.

METHODS

This study was conducted at Ankara Training and Research Hospital Animal Testing Laboratory on 36 female Wistar albino rats, aged 6-8 months and weighing between 200-230 grams. We chose all female rats to ensure that the results are not affected by sex hormones. The rats used in the study were kept at the Ankara Training and Research Hospital Animal Testing Laboratory in standard cage conditions, in cages of 4 with standard feed, water and libitum for the 42-day duration of the study. Model of Ishii *et al.*, 0,1% Chlorhexidine (CH), 15% ethanol, serum physiologic (SP) mixture was prepared aseptically and utilized to induce peritoneal fibrosis.⁽¹³⁾ Group I was the control group. Group II, the placebo group, was administered intraperitoneal Chlorhexidine (Drogsan drug Inc.) at a dose of 10 mg/kg/day for 21 days, followed by 3 weeks of 2 ml SP through a nasogastric catheter. Group III, the resting group, was administered intraperitoneal CH at a dose of 10 mg/kg/day for 21 days. Group IV was administered 10 mg/kg/day of intraperitoneal CH for 21 days followed by 21 days of 0.2 mg/kg/day of Tac (Prograf®, Astellas Pharma Inc.) bi-daily through a nasogastric catheter. Group V was administered intraperitoneal CH at a dose of 10 mg/kg/day for 21 days followed by 0.2 mg/kg/day of nasogastric Tac, administered concurrently with CH for 42 days. Group VI was administered intraperitoneal CH at a dose of 10 mg/kg/day for 21 days followed by 21 days of 0.2 mg/kg/day of Tac and 25 mg/day of MMF (Cellcept®, Hoffmann-La Roche Inc) together through a nasogastric tube (**Table 1**). A 21 G needle was used in all intra-abdominal injections. Injections were performed daily at the inferior part of the

peritoneal cavity and the parietal peritoneum on the upper left quadrant of the abdomen was used for pathological examinations to ameliorate the impact of direct damage created by repeated injections on the peritoneum. At the end of the study period, pre-anaesthetic pain control was ensured with 5 mg/kg intramuscular (i.m.) xylocaine (Rompun®, Bayer inc). For anesthesia, 50 mg/kg of i.m. ketamine hydrochloride (Ketalar®, Pfizer Inc) was administered and the rats were subsequently sacrificed. Parietal peritoneal samples were fixed in 10% neutral buffered formalin, embedded in paraffin and examined microscopically with hematoxylin-eosin and Masson's trichrome stains. In addition, all samples were stained immunohistochemically with matrix metalloproteinase-2 (MMP-2) antibody. Peritoneal samples were examined histopathologically for peritoneal fibrosis thickness, subserosal large collagen fibers, subserosal fibroblast proliferation and subserosal fibrotic matrix deposition. In addition, inflammation score and fibrosis score was established. In the study conducted by Ishii Y *et al.* fibrosis score consisted of the total of the scores for subserosal fibrotic matrix, subserosal fibroblast proliferation and large subserosal collagen fibers. Fibrosis score was rated in a range that varied from a mild edema (0 points) to severe fibrosis (5 points).⁽¹⁶⁾

Subserosal fibrotic matrix: 0=none, 1=mild, 2=marked

Large subserosal collagen fibers: 0=none, 1=present

Subserosal fibroblast proliferation: 0=none, 1=mild, 2=marked

Again, as in the study conducted by Ishii *et al.*, inflammation scoring was made by assessing it in 4 phases.⁽¹⁶⁾

0 = None or sporadic presence of inflammatory cells

1 = Mild inflammation: Presence of few dispersed inflammatory cells

2 = Moderate inflammation: Presence of inflammatory cells in small groups in many large magnified areas

3 = Severe inflammation: Presence of inflammatory cells in diffused pattern or in large groups.

Table 1. Characteristics of the groups

Groups	Used drugs	Number of animals per group
Group I [#]	Serum physiologic (SP)	6
Group II	Chlorhexidine (CH) + serum physiologic (SP)	6
Group III	Chlorhexidine (CH)	6
Group IV	Chlorhexidine (CH) + Tacrolimus (Tac)	6
Group V*	Chlorhexidine (CH) + Tacrolimus concurrently	6
Group VI	Chlorhexidine (CH) + Tacrolimus (Tac) + Mycophenolat mofetil (MMF)	6
Total number of animals used	36	36

[#] Group I is control group
^{*}Group V which is administered chlorhexidine and tacrolimus together was for 6 weeks

Immunohistochemical evaluation

Peritoneal membrane samples from all groups were evaluated for staining with MMP-2 antibody. Fibroblasts and macrophages that gave a positive cytoplasmic reaction with MMP-2 stain were evaluated semiquantitatively. The study was approved by the local ethics committee of clinical animal research (decision number 2012/115, dated: 05/31/2012)

Statistical analysis

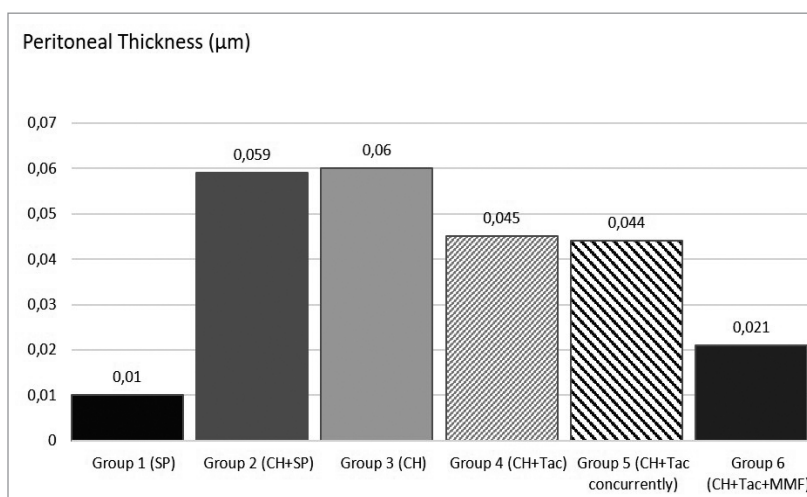
Multiple comparisons between groups were performed by one-way analysis of variance with post-hoc Tukey test correction (SPSS® version 15.0; SPSS, Chicago, IL, US). Comparisons among two groups were performed using a t-test. The level of statistical significance was set as $p < 0.05$. Chi-squared and Kruskal–Wallis tests were used to compare non-parametric data of the

groups.

RESULTS

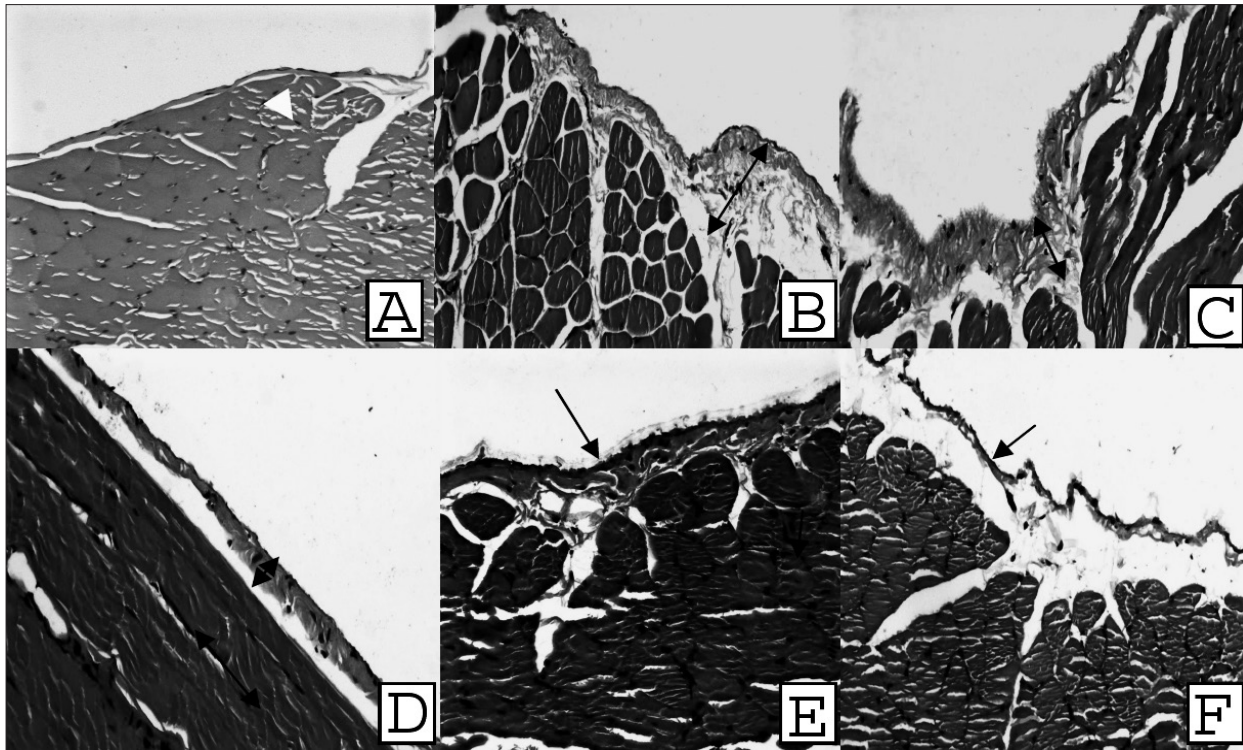
All 36 rats completed the study. While rats in the Group II and III had macroscopic thickening of the parietal peritoneum and adhesions to the abdominal wall, these findings were not observed in the Group I. Parietal peritoneal thicknesses of all groups were compared and statistically significant differences were observed in terms of peritoneal thickness between any groups ($p < 0.05$). Group II and III had the most increase in peritoneal thickness and group VI had the least amount of peritoneal thickening among all groups, excluding the control group (**Figure 1**). The peritoneal thicknesses in Group IV and V were detected greater than Group VI. Histopathological images of all groups are shown in **Figure 2**.

Figure 1. Parietal peritoneal thicknesses of all groups (in micrometers)



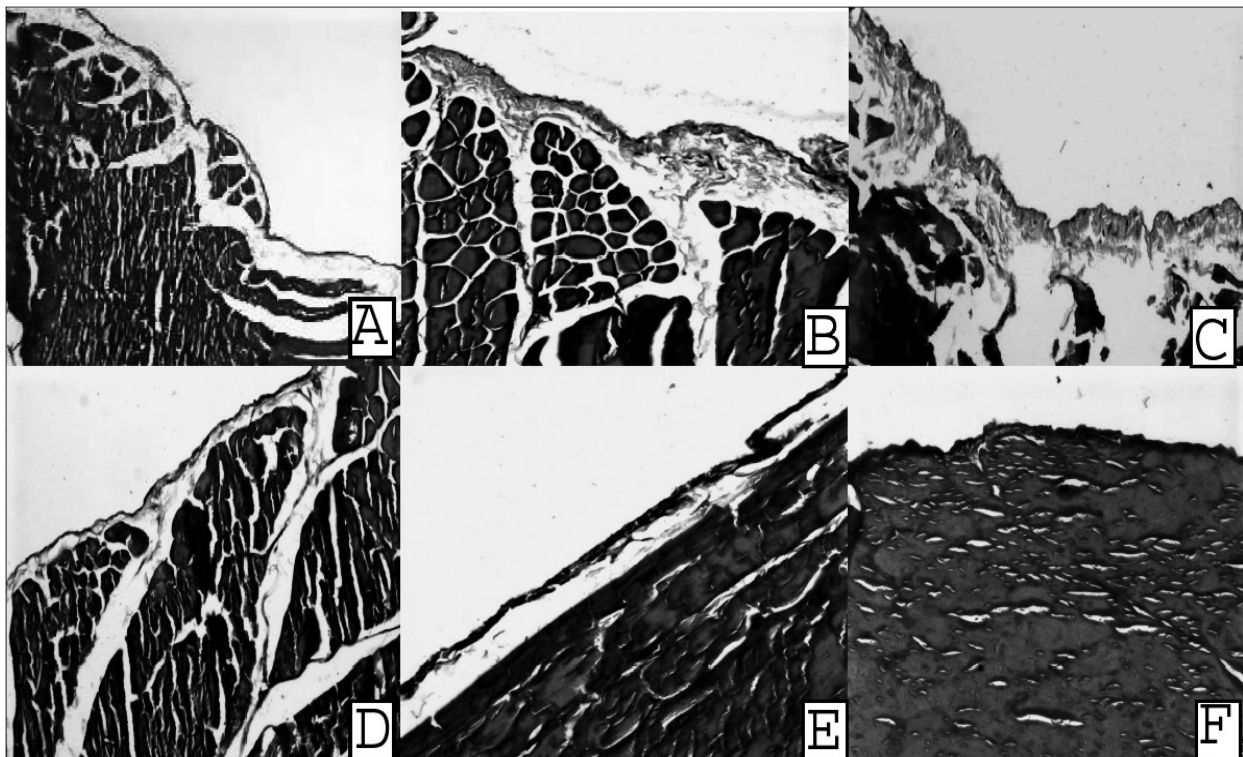
Parietal peritoneal thicknesses of all groups were compared and statistically significant differences were observed in terms of peritoneal thickness among all groups ($p < 0.05$).

Figure 2. Peritoneal membrane images (H&EX20) for all groups



A: Group I, B: Group II C: Group III, D: Group IV, E: Group V, F: Group VI

Figure 3. Peritoneal membrane and fibrosis images (Masson's trichrom X20) for all groups



A: Group I, B: Group II, C: Group III, D: Group IV, E: Group V, F: Group VI

Figure 3 represents peritoneal thickness and fibrosis with Masson’s trichrome stain for each group. Similarly, parietal peritoneal thickening and fibrosis in Group II and III were found to be the greatest, while the thickening and fibrosis in Group VI was found to be the closest to the control group. Group IV and VI were also comparable in terms of parietal peritoneal thickening and fibrosis.

Average and Standard Deviation values for inflammation scoring, subserosal fibroblast proliferation, number of large subserosal collagen fibers, subserosal fibrotic matrix and fibrosis score were calculated. Statistically significant differences were detected between the treatment groups (group IV, V, VI) and the control groups ($p < 0.05$). (**Table 2**)

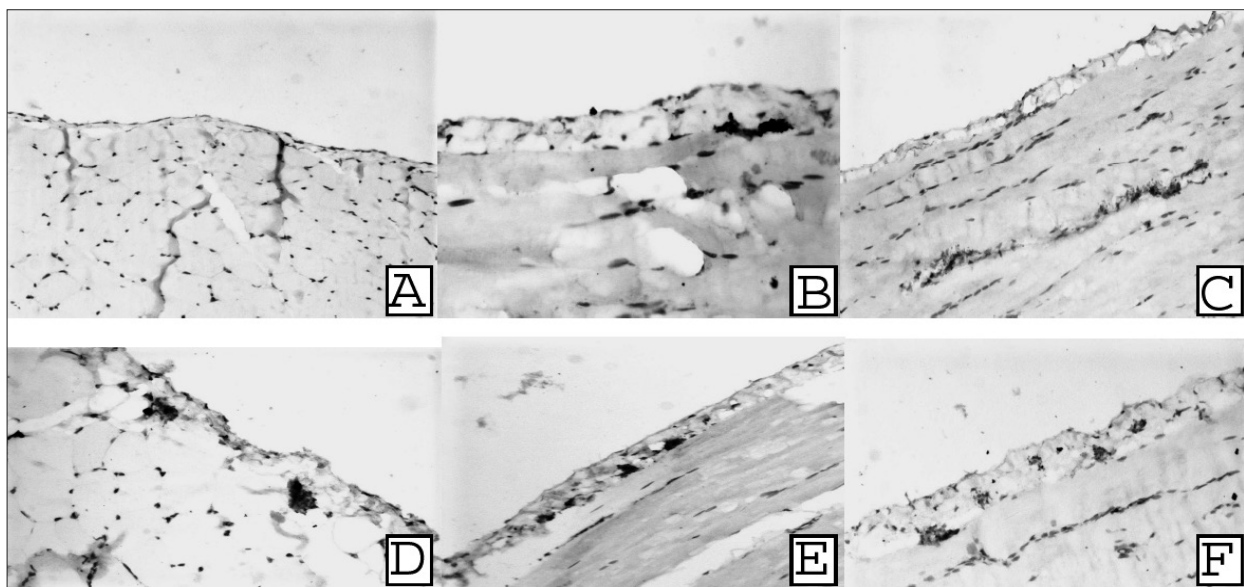
Table 2. Histopathological assessment of peritoneal samples

Group	I	II	III	IV	V	VI	p
PT	0.01 ±0.002	0.059 ±0.009	0.06 ±0.009	0.045 ±0.01	0.044 ±0.006	0.021 ±0.005	0.000
IS	0±0	1.16±0.4	1.3±0.51	0.6±0.51	0.6±0.51	0.3±0.51	0.000
SFP	0±0	1.3±0.51	1.5±0.54	0.5±0.54	0.3±0.51	0.16±0.4	0.000
LSCF	0±0	0.6±0.51	1±0	0.5±0.54	0.5±0.54	0.3±0.51	0.013
SFM	0±0	1.3±0.51	1.5±0.54	0.8±0.75	0.5±0.54	0.3±0.51	0.000
Fibrosis Score	0±0	3.3±1.2	4±0.89	1.8±1.6	1.3±0.81	0.8±0.75	0.000

Peritoneal membrane samples of all groups were evaluated. Staining with MMP-2 antibody was detected in peritoneal membrane samples of the SP group as a result of the macroscopic evaluation. There has been moderate staining in fibroblasts and macrophages in Group II and III while increased staining in Group IV, V and

VI compared to non-treatment groups (I, II, III). Similarly, there was frequent staining with MMP-2 in fibroblasts and macrophages in Group IV, V and VI. Group VI was significantly different even when compared to the other treatment groups (Group IV and V) (**Figure 4**).

Figure 4. MMP-2 stain images (X20) for all groups



A: Group I, **B:** Group II, **C:** Group III, **D:** Group IV, **E:** Group V, **F:** Group VI

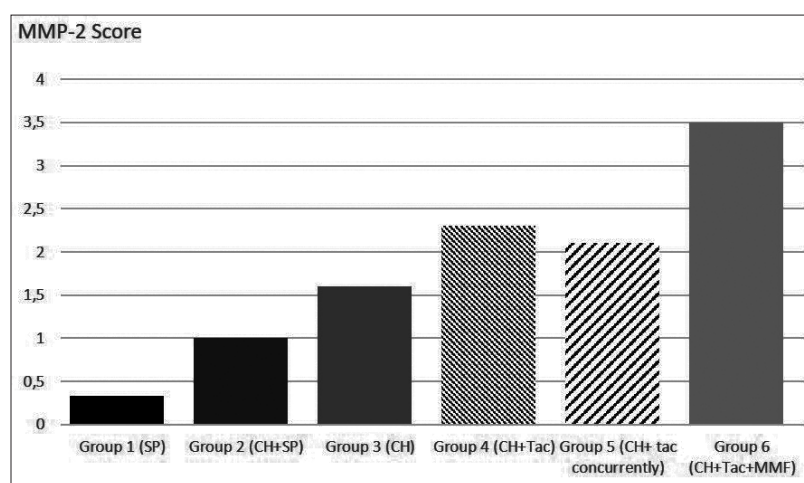
A graph of average MMP2 staining scores for all groups is shown in (Table 3, Figure 5). In the analysis of scoring of fibroblasts and macrophages

which reacts positively with MMP-2 antibody within each group, statistically significant differences were found ($p=0.004$)

Table 3. MMP-2 scoring averages for all groups

	MMP-2 Score
Group I	0,33 ± 0,51
Group II	1 ± 0,63
Group III	1,6 ± 1,2
Group IV	2,3 ± 1,8
Group V	2,1± 1,7
Group VI	3,5 ± 1,2
p	0,004

Figure 5. MMP-2 scoring averages for all groups



DISCUSSION

Tacrolimus is an immunosuppressive agent thought to function through the inhibition of calcineurin as well as inhibition of antigen specific T cell activation and the release of inflammatory cytokines such as IL-4, IL-5 and IL-2.⁽³⁾ However, tacrolimus is known to have effects that trigger fibrosis due to its prolonged use with cyclosporine (CsA), another calcineurin inhibitor, following transplantations.^(10, 17-18) There are contrary studies showing tacrolimus to also have antifibrotic effects and effects that prevent intimal hyperplasia.^(9, 19) MMF is another immunosuppressive agent that is a noncompetitive inhibitor of the inosine monophosphate dehydrogenase enzyme (IMPDH) that has anti-inflammatory and antifibrotic effects. There are quite a few studies that have demonstrated inhibitory antifibrotic effects of MMF on fibroblasts and vascular smooth muscle cells.⁽²⁰⁻²²⁾

In our study there were statistically significant differences in terms of all histopathological

parameters in the MMF+Tac group ($p<0.05$).

While no statistically significant difference was found in terms of large subserosal collagen fibers between groups IV and V where we administered tacrolimus therapy from the start and from the time when fibrosis occurred ($p=0.55$), statistically significant differences were found in terms of other parameters. This shows us that administration of MMF together with tacrolimus helps to achieve remission in subserosal fibroblast proliferation, large subserosal collagen fibers, subserosal fibrotic matrix, inflammation score, fibrosis score and peritoneal thickness and has regressive effects on peritoneal fibrosis. That significant difference was detected in parameters except for one parameter in groups which are administered tacrolimus only, we believe indicates that tacrolimus therapy alone also causes some amount of remission in fibrosis although not as much as in the group that was administered concurrent Tac and MMF therapy.

We compared placebo and treatment groups,

statistically significant differences were detected in all parameters except for large subserosal collagen fibers in the group which was administered MMF and Tac. No significant difference was found in the group which was administered Tac in terms of inflammation score, large subserosal collagen fibers and subserosal fibrotic matrix. Considering these results, the regression in fibrosis indicators compared to placebo showed that Tac and MMF combination therapy is more effective than Tac therapy alone.

In comparisons made within the groups that were given only Tac, no statistically significant difference was found when compared with the placebo group ($p > 0.05$). A statistically significant difference with placebo was only detected in the group in which we administered Tac and MMF in combination ($p = 0.002$). A statistically significant difference was also found with the CH group between the Tac and MMF combination group ($p = 0.02$).

There are no studies available regarding the effects of tacrolimus on peritoneal fibrosis; however, there are studies regarding non peritoneal tissues which demonstrate both its fibrosis stimulating and antifibrotic effects. In a study conducted by Manojlovic Z *et al.*, tacrolimus was shown to prevent hepatic fibrosis induced by ethanol by inhibiting type 1 collagen and alpha smooth muscle actin (α -SMA) synthesis without affecting mRNA expression in mice.⁽²³⁾ In a study conducted by Nagano J *et al.* on mice, tacrolimus was shown to regress fibrosis by repressing T β R-I (TGF- β type I receptor) expression in lung fibrosis induced by bleomycin.⁽⁹⁾ In another study conducted by Waller JR *et al.* on mice, in order to prevent allograft vasculopathy, reduction in vascular intimal thickness, regression of intimal hyperplasia and marked decrease in extracellular matrix accumulation compared to the combination made with cyclosporine was detected as a result of the effect on profibrotic gene expression due to the combined use of rapamycin with tacrolimus.⁽²⁴⁾ Although the studies regarding the effects of tacrolimus on peritoneal fibrosis are not sufficient, according to the results of our study, we believe that the mechanisms of fibrosis formation are similar across all tissues and tacrolimus has the same effects in the peritoneum as well.

In addition to the studies demonstrating antifibrotic properties of tacrolimus, Khanna A *et*

al. demonstrated in their study that it has other fibrosis triggering effects by increasing TGF- β synthesis in case of prolonged use following transplantation as CsA, which is another calcineurin inhibitor.⁽¹⁰⁾ Bicknell GR *et al.* examined renal biopsies of patients receiving Tac and CsA as immunosuppressive therapy following renal transplantation and they found that both drugs had fibrotic effects, however, Tac had much less fibrotic effects compared to CsA.⁽¹¹⁾ In our study, contrary to studies showing its fibrosis stimulating effect, we detected regression in peritoneal thickness and other fibrosis indicators in the groups which we administered Tac compared to placebo. This gives us an important reference in favor of choosing combinations with tacrolimus in case of transplantations made to patients who have a history of long term peritoneal dialysis in order to prevent peritoneal fibrosis that may develop after transplantation.

Our study showed no statistically significant difference between administration of Tac for 6 weeks concurrently with CH and only for 3 weeks following the administration of CH in terms of any parameters which are indicators of fibrosis ($p > 0.05$). We believe this result indicates that Tac is not effective in preventing fibrosis development, but it regresses the fibrosis that has already developed.

In the study by Badid *et al.* reduction in fibroblast motility was detected with MMF treatment. MMF was also shown to suppress α -SMA gene expression and to inhibit fibrosis as a result.⁽²²⁾ In support of other studies, our study also indicated significant regression in peritoneal thickness and other indicators of fibrosis in the group to whose therapy MMF was added compared to groups which were administered Tac only. We believe this effect is elicited with the combined antifibrotic effect of concurrently administered immunosuppressive agents concurrently, primarily of MMF.

In another study conducted by Luo L *et al.* MMF and Tac therapy were administered to rats which underwent transplantation and compared in order to investigate its effects on chronic allograft nephropathy. It was shown that MMF helped to alleviate renal fibrosis and allograft

rejection regress by suppressing TGF- β and α -SMA gene expression. Contrarily, Tac was shown to trigger fibrosis.⁽²⁵⁾ Our study found

effects in favor of fibrosis regression in Tac therapy alone and Tac therapy together with MMF. However antifibrotic and antiinflammatory effects were more apparent in the group with MMF therapy. The reason why there was no statistically significant difference for inflammation score, large subserosal collagen fibers and fibrotic matrix in the group to which Tac was administered may be explained by the more potent antifibrotic effects of MMF and the presence of fibrosis stimulating effects of Tac.

In the study conducted by Martin J *et al.* the presence of MMP-2, MMP-3 MMP-9, TIMP-1 and TIMP-2 activities in peritoneal cell cultures was shown.⁽⁴⁾ Again in studies of Masunaga Y *et al.* and Fukudome K *et al.*, increase in MMP-2, MMP-9 and TIMP-1 in the peritoneal fluid during peritoneal fibrosis and peritonitis was demonstrated.^(5,16) In another study, it was detected that MMP-2 activity in the dialysate fluid increased in rats in which encapsulating peritonitis was induced.⁽²⁾ Therefore, in the next part of our study, we compared the CH group and the treatment groups in which we used Tacrolimus and MMF in terms of MMP-2 at the tissue level.

In a study conducted by Doller A *et al.* MMP-9 increase induced by cytokines in glomerular mesangial cells as well as the effect of CsA and Tac were assessed, and it was suggested that the decrease in MMP-9 and the proportional increase in its inhibitor induced fibrosis in the kidneys. At the end of the study, it was found that CsA inhibits transcription factors of NF-Kb and AP-1, inhibits MMP-9 expression, on the other hand, tacrolimus has very weak effects on these transcription factors.⁽²⁶⁾ In the study conducted by Gagliano N *et al.* Tac therapy was shown to reduce gingival overgrowth. It was shown to have this effect through increasing MMP-1 gene and protein expression, MMP-2 and mRNA levels.⁽²⁷⁾

We detected that the staining level which is the indicator of MMP-2 level was the highest in the group in which we administered MMF and Tac combination. The groups that received Tac alone had comparable MMP-2 staining among themselves, and the staining was found to be diminished compared to the group given MMF with TAC combination therapy.

In our study, only MMP-2 was evaluated in the peritoneal membrane and TIMPs which are inhibitors of MMPs were not studied. Therefore;

we currently do not have an insight into about the ratios of MMPs and TIMPs which are known to be in equilibrium with each other in the new extracellular structure. This equilibrium is distorted in favor of inhibitors during the fibrosis process. In the study conducted by Nina Roos *et al.*, MMF therapy was shown to increase gene expression of MMP-1 level and mRNA level associated with time and thus increase MMP level and the antifibrotic effect was shown to occur through increasing matrix metalloproteinase level and increasing collagen destruction.⁽²¹⁾

When MMP-2 results of our study were considered, we have associated the fact that MMP-2 staining in the tissue in the group to which we administered MMF and Tac together was significantly higher than the control group, CH+SP group and Tac group, suggesting that MMF increases matrix metalloproteinases and its therapeutic effect occurs through this mechanism. Similar effects were shown in studies conducted with tacrolimus; however, there are also studies in which Tac has fibrosis triggering effects. Our study demonstrated that administration of Tac alone may have fibrosis regression effects although not as much compared to its combination with MMF. It is difficult to comment on whether the positive effects of the combination of MMF and Tac on fibrosis is due to antifibrotic effects of both drugs separately or due to the potent antifibrotic effectiveness of MMF alone. There is a need for comparative studies in which MMF is also used alone.

MMF and Tac are commonly used after renal transplantation in order to prevent rejection attacks. We believe that the positive impact of MMF and Tac on peritoneal fibrosis and EPS, which develop especially in patients who undergo transplantation following peritoneal dialysis and which have negative effects on the transplantation survival, would make the combination of these drugs more reasonable for this patient group. As expected, in every group that was administered chlorhexidine, we achieved significant peritoneal thickening compared to the control group. We found that both immunosuppressive therapies (tacrolimus and mycophenolate mofetil) which we applied to our rat model of EPS were effective in reducing peritoneal fibrosis and better results could be achieved with concurrent use of these two immunosuppressive therapies.

BIBLIOGRAPHY

- 1) Krediet RT. 30 years of peritoneal dialysis development: the past and the future. *Perit Dial Int.* 2007;27 (Suppl 2):S35-41.
- 2) Hirahara I, Inoue M, Okuda K, Ando Y, Muto S, Kusano E. The potential of matrix metalloproteinase-2 as a marker of peritoneal injury, increased solute transport, or progression to encapsulating peritoneal sclerosis during peritoneal dialysis: a multicentre study in Japan. *Nephrol Dial Transplant.* 2007;22(2):560-7. doi: 10.1093/ndt/gfl566.
- 3) Hung KY, Huang JW, Tsai TJ, Hsieh BS. Peritoneal fibrosing syndrome: pathogenetic mechanism and current therapeutic strategies. *J Chin Med Assoc.* 2005;68(9):401-5. doi: 10.1016/S1726-4901(09)70154-6.
- 4) Martin J, Yung S, Robson RL, Steadman R, Davies M. Production and regulation of matrix metalloproteinases and their inhibitors by human peritoneal mesothelial cells. *Perit Dial Int.* 2000;20(5):524-33.
- 5) Fukudome K, Fujimoto S, Sato Y, Hisanaga S, Eto T. Peritonitis increases MMP-9 activity in peritoneal effluent from CAPD patients. *Nephron.* 2001;87(1):35-41. doi: 10.1159/000045882.
- 6) Nghiem P. "Topical immunomodulators?": introducing old friends and a new ally, tacrolimus. *J Am Acad Dermatol.* 2001;44(1):111-3. doi: 10.1067/mjd.2001.110902.
- 7) Suzuki S, Toledo-Pereyra LH, Rodriguez FJ, Cejalvo D. Neutrophil infiltration as an important factor in liver ischemia and reperfusion injury. Modulating effects of FK506 and cyclosporine. *Transplantation.* 1993;55(6):1265-72. doi: 10.1097/00007890-199306000-00011.
- 8) Anglicheau D, Legendre C, Beaune P, Thervet E. Cytochrome P450 3A polymorphisms and immunosuppressive drugs: an update. *Pharmacogenomics.* 2007;8(7):835-49. doi: 10.2217/14622416.8.7.835.
- 9) Nagano J, Iyonaga K, Kawamura K, Yamashita A, Ichiyasu H, Okamoto T, et al. Use of tacrolimus, a potent antifibrotic agent, in bleomycin-induced lung fibrosis. *Eur Respir J.* 2006;27(3):460-9. doi: 10.1183/09031936.06.00070705.
- 10) Khanna A, Plummer M, Bromberek C, Bresnahan B, Hariharan S. Expression of TGF-beta and fibrogenic genes in transplant recipients with tacrolimus and cyclosporine nephrotoxicity. *Kidney Int.* 2002;62(6):2257-63. doi: 10.1046/j.1523-1755.2002.00668.x.
- 11) Bicknell GR, Williams ST, Shaw JA, Pringle JH, Furness PN, Nicholson ML. Differential effects of cyclosporin and tacrolimus on the expression of fibrosis-associated genes in isolated glomeruli from renal transplants. *Br J Surg.* 2000;87(11):1569-75. doi: 10.1046/j.1365-2168.2000.01577.x.
- 12) Hur E, Bozkurt D, Timur O, Bicak S, Sarsik B, Akcicek F, et al. The effects of mycophenolate mofetil on encapsulated peritoneal sclerosis model in rats. *Clin Nephrol.* 2012;77(1):1-7. doi: 10.5414/cn107140.
- 13) Huddam B, Başaran M, Koçak G, Azak A, Yalçın F, Reyhan NH, et al. The use of mycophenolate mofetil in experimental encapsulating peritoneal sclerosis. *Int Urol Nephrol.* 2015;47(8):1423-8. doi: 10.1007/s11255-015-1015-z.
- 14) Lafrance JP, Létourneau I, Ouimet D, Bonnardeaux A, Leblanc M, Mathieu N, et al. Successful treatment of encapsulating peritoneal sclerosis with immunosuppressive therapy. *Am J Kidney Dis.* 2008;51(2):e7-10. doi: 10.1053/j.ajkd.2007.07.036.
- 15) Jiang S, Tang Q, Rong R, Tang L, Xu M, Lu J, et al. Mycophenolate mofetil inhibits macrophage infiltration and kidney fibrosis in long-term ischemia-reperfusion injury. *Eur J Pharmacol.* 2012;688(1-3):56-61. doi: 10.1016/j.ejphar.2012.05.001.
- 16) Ishii Y, Sawada T, Shimizu A, Tojimbara T, Nakajima I, Fuchinoue S, et al. An experimental sclerosing encapsulating peritonitis model in mice. *Nephrol Dial Transplant.* 2001;16(6):1262-6. doi: 10.1093/ndt/16.6.1262.
- 17) Fieren MW, Betjes MG, Korte MR, Boer WH. Posttransplant encapsulating peritoneal sclerosis: a worrying new trend? *Perit Dial Int.* 2007;27(6):619-24.
- 18) Korte MR, Habib SM, Lingsma H, Weimar W, Betjes MG. Posttransplantation encapsulating peritoneal sclerosis contributes significantly to mortality after kidney transplantation. *Am J Transplant.* 2011;11(3):599-605. doi: 10.1111/j.1600-6143.2010.03434.x.
- 19) Waller JR, Brook NR, Bicknell GR, Nicholson ML. Differential effects of modern immunosuppressive agents on the development of intimal hyperplasia. *Transpl Int.* 2004;17(1):9-14. doi: 10.1007/s00147-003-0653-8.
- 20) Gregory CR, Pratt RE, Huie P, Shorthouse R, Dzau VJ, Billingham ME, et al. Effects of treatment with cyclosporine, FK 506, rapamycin, mycophenolic acid, or deoxyspergualin on vascular muscle proliferation in vitro and in vivo. *Transplant Proc.* 1993;25(1 Pt 1):770-1.
- 21) Roos N, Poulalhon N, Farge D, Madelaine I, Mauviel A, Verrecchia F. In vitro evidence for a direct antifibrotic role of the immunosuppressive drug mycophenolate mofetil. *J Pharmacol Exp Ther.* 2007;321(2):583-9. doi:

- 10.1124/jpet.106.117051.
- 22) Badid C, Vincent M, McGregor B, Melin M, Hadj-Aissa A, Veysseyre C, et al. Mycophenolate mofetil reduces myofibroblast infiltration and collagen III deposition in rat remnant kidney. *Kidney Int.* 2000;58(1):51-61. doi: 10.1046/j.1523-1755.2000.00140.x.
- 23) Manojlovic Z, Blackmon J, Stefanovic B. Tacrolimus (FK506) prevents early stages of ethanol induced hepatic fibrosis by targeting LARP6 dependent mechanism of collagen synthesis. *PLoS One.* 2013;8(6):e65897. doi: 10.1371/journal.pone.006589.
- 24) Waller JR, Murphy GJ, Bicknell GR, Toomey D, Nicholson ML. Effects of the combination of rapamycin with tacrolimus or cyclosporin on experimental intimal hyperplasia. *Br J Surg.* 2002;89(11):1390-5. doi: 10.1046/j.1365-2168.2002.02271.x.
- 25) Luo L, Sun Z, Wu W, Luo G. Mycophenolate mofetil and FK506 have different effects on kidney allograft fibrosis in rats that underwent chronic allograft nephropathy. *BMC Nephrol.* 2012;13:53. doi: 10.1186/1471-2369-13-53.
- 26) Doller A, Akool el-S, Müller R, Gutwein P, Kurowski C, Pfeilschifter J, et al. Molecular mechanisms of cyclosporin A inhibition of the cytokine-induced matrix metalloproteinase-9 in glomerular mesangial cells. *J Am Soc Nephrol.* 2007;18(2):581-92. doi: 10.1681/ASN.2006060568.
- 27) Gagliano N, Moscheni C, Dellavia C, Stabellini G, Ferrario VF, Gioia M. Immunosuppression and gingival overgrowth: gene and protein expression profiles of collagen turnover in FK506-treated human gingival fibroblasts. *J Clin Periodontol.* 2005;32(2):167-73. doi: 10.1111/j.1600-051X.2005.00654.x.